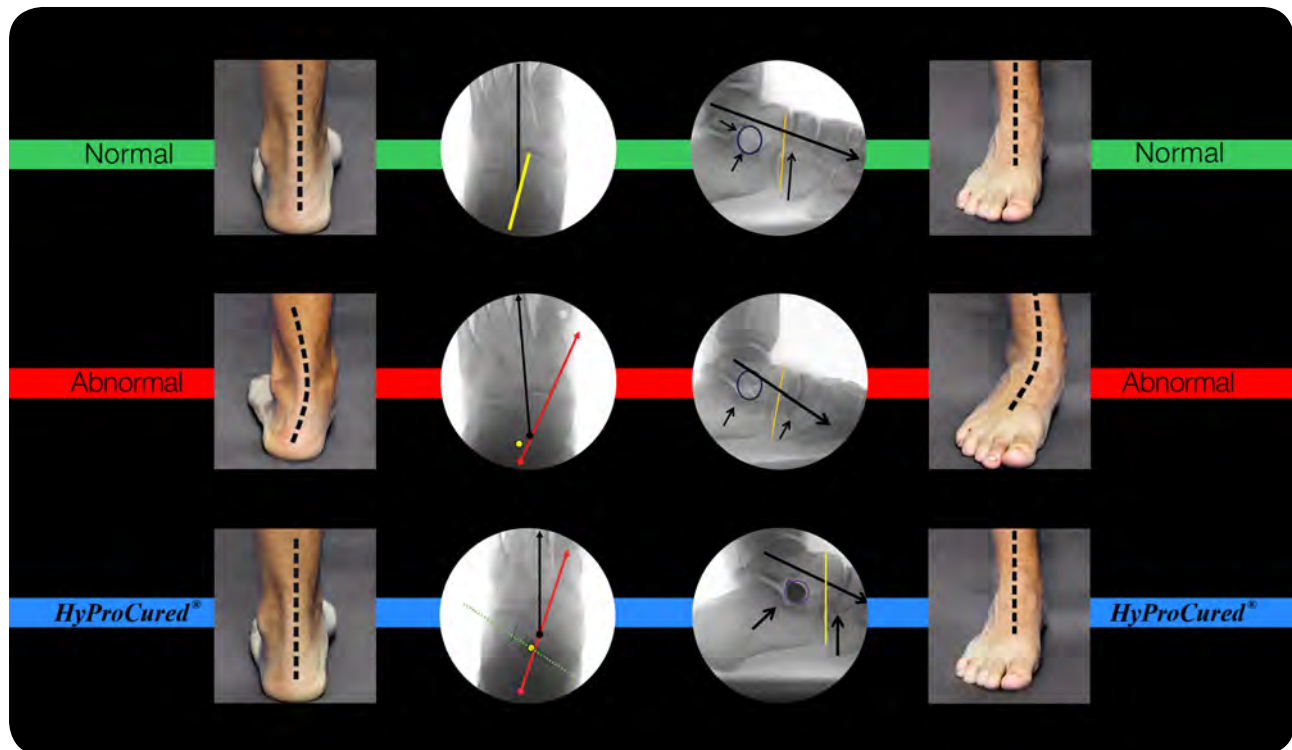


HyProCure®

Extra-Osseous TaloTarsal Stabilization



by Michael E. Graham, DPM, FACFAS, FAENS
Macomb, Michigan USA



All rights reserved. No part of this publication may be reproduced, distributed, or transmitted in any form or by any means, including photocopying, recording, or other electronic or mechanical methods, without the prior written permission of the publisher, except in the case of brief quotations embodied in critical reviews and certain other noncommercial uses permitted by copyright law.

Introduction

Many people suffer needlessly from the far-reaching effects of excessive hindfoot motion. This is due in part to a lack of awareness of the effects of this condition and in part to a lack of faith in the “traditional” treatment options available.

Talotarsal displacement is a result of a congenital malformation where the talus partially dislocates its articular facets on the calcaneus and navicular. This condition can be described as mild, moderate or severe; flexible, semi-flexible or rigid. The pathologic condition leads to a chain reaction of damage distally throughout the foot and proximally up the musculoskeletal chain. There is an unnatural shift of forces acting on the joints and soft tissues when weightbearing that, when added to the repetitive walking/running gait cycles, eventually leads to painful secondary conditions.

The leading long-term complication in the treatment of musculoskeletal conditions is recurrence of the treated condition, i.e. back surgery, hip and knee joint replacement, bunion surgery. The reason why there is such a high long-term failure rate is that often the underlying etiology - talotarsal displacement - is not appropriately addressed. Arch supports/orthoses are merely temporary, external solutions, while traditional hindfoot reconstructive surgery is simply too aggressive for most patients; hence the need for EOTTS (Extra-Osseous TaloTarsal Stabilization).

The purpose of this guide is to provide you and your staff with the keys to successful implementation of EOTTS in your practice. We are dedicated to supporting you in delivering positive outcomes for your patients.

We care greatly about your personal satisfaction with EOTTS, so please let us know what we can do to increase your success.

*Michael E. Graham, DPM, FACFAS, FAENS
Founder & CEO, GraMedica
Founder & Director, Graham International Implant Institute*

This page intentionally left blank.

Table of Contents

Introduction	3
Patient History & Physical Examination	7
Patient Questionnaire & Consultation	7
Non-Weightbearing Examination	7
Weightbearing Examination	12
Gait Analysis	16
Weightbearing Radiographs Evaluation	17
DP View	19
Lateral View	21
X-ray Comparison Views	24
Patient Selection: Indications & Contra-Indications	27
EOTTS – Transverse Plane Correction (Talar Second Metatarsal Angle)	29
EOTTS – Saggital Plane Correction (Talar Declination Angle)	30
EOTTS Has Its Limitations	32
Diagnosis & Treatment Options	33
Sample Script for Patient Discussion/Presentation	33
Other Sample Dialogs	35
Heel Pain/Plantar Fasciopathy	35
Bunions	36
Hallux Limitus/Rigidus - Limited Big Toe Joint Motion	37
Posterior Tibial Tendinitis	38
Knee Pain	39
Hip/Back Pain	39
EOTTS – HyProCure® Preferred Surgical Technique	41
Pre-Op Antibiosis.....	41
Hemostasis.....	41
Landmarks.....	42
Pre-op Sinus Tarsi Injection.....	43
STEP 1: Skin Incision.....	45
STEP 2: Blunt Dissection.....	45
STEP 3: Sinus Tarsi Decompression.....	46
STEP 4: Trial Sizing – Determining the Size of the HyProCure® Device.....	47
STEP 5: HyProCure® Stent Placement	54
STEP 6: Closure.....	61
STEP 7: Bandaging.....	62

Table of Contents

Immediate Post-Op (Suggested) Protocol	63
Post-Operative Pain Management	71
EOTTS Troubleshooting Guide	75
Ankle Pain	75
Pain Management	76
Stent Displacement	76
Course of Action for Stent Displacement	79
Stent Revision & Repositioning	80
Under- or Over-Correction	80
Failure to Achieve the Desired Result	81
Psychological Reaction/Rejection	82
Surgical Technique for Removal/Revision	82
EOTTS Check Lists	83
EOTTS – HyProCure® Patient Selection Check List	83
Patient Clinical Examination: Be On The Look Out Check List	85
EOTTS – HyProCure® Surgical Procedure Check List	87
EOTTS – HyProCure® Patient Pain Check List	89
Staff Resources	91
DP and Lateral Radiographic Comparison Technique	91
Radiographic Positioning Guide	92
EOTTS – HyProCure® Procedure Check List	93
Benefit-Risk Analysis of Extra Osseous-Talotarsal Stabilization	95
EOTTS – No Guarantees	101
Extra-Osseous TaloTarsal Stabilization with Internal Fixation Surgical Consent Addendum	103
PRE-EOTTS Surgical Instructions	105
POST-EOTTS Instructions	107
Post-EOTTS Hints	109

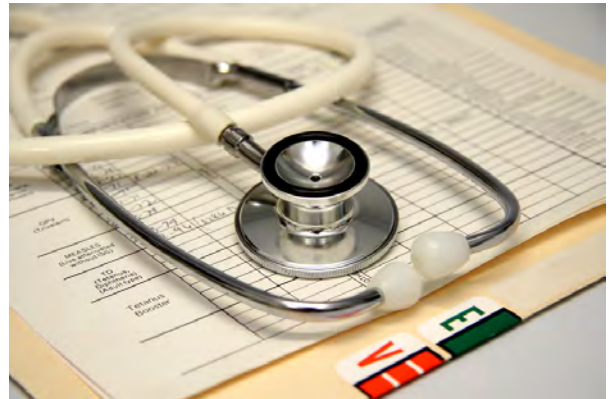Patient History & Physical Examination

Patients present to your clinic because they have a symptom. Something hurts or bothers them and they can't make it go away, so they need your help. Please remember the rule of "cause and effect." The effect is the symptom (plantar fasciitis, posterior tibial tendonitis, 1st ray disorders – such as bunions/hallux limitis/rigidus, nerve entrapments, altered gait pattern, shin splints, growing pains, knee, hip and back issues); the goal is to reduce the symptoms while at the same time eliminating the cause of the symptom.

As you interview your patient regarding their chief complaint, remember to focus on the functional symptoms: discover if they suffer more with increased activity.

Patient Questionnaire & Consultation

Frequently, by the time a patient comes to see you, they will have already tried other remedies or consulted with other health care providers and come away with an unsatisfactory outcome. A thorough history not only presents an opportunity to discuss why these options have been less than successful, it adds to the growing body of evidence that their mis-aligned feet may be the source of the problems.



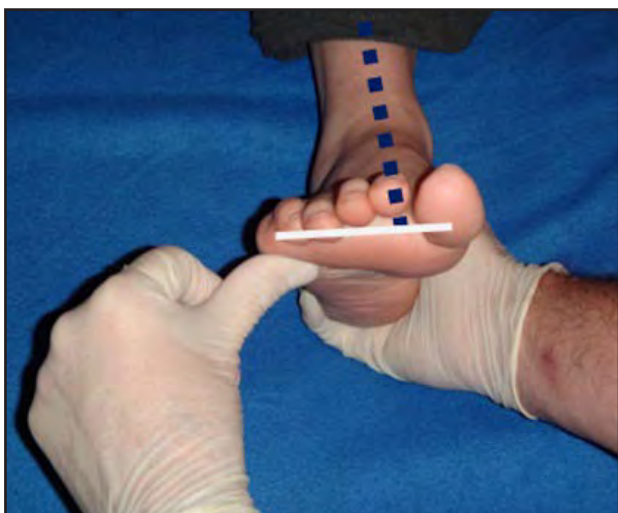- Does the patient have a history of foot, knee, hip or back problems?
- Has the patient been treated by a chiropractor or orthopedist for musculoskeletal complaints?
- Has the patient been treated by any other foot specialists?
- Does the patient suffer from "functional symptoms," that is, the more active they are, the more they suffer?
- Does the patient have a history of growing pains or shin splints?
- Has the patient tried wearing arch supports, orthoses or different shoes?

Non-Weightbearing Exam

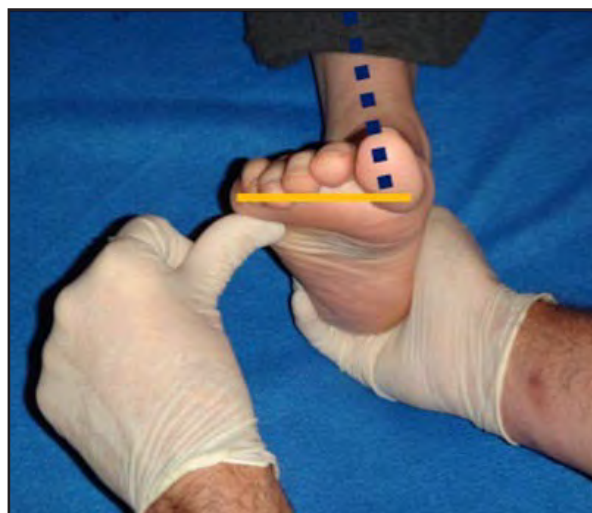We understand that you are an expert at examining patients' feet; however, when it comes to accurately diagnosing flexible partial dislocation of the talotarsal mechanism, please consider these additional pointers.

>> *TaloTarsal Joint Range of Motion*

The best way to check the range of talotarsal motion is to load the lateral column of the foot by applying dorsolateral pressure under the 4th & 5th metatarsal heads.



Talotarsal Neutral Position



Normal Maximum Pronation

The above images show a normal amount of talotarsal motion. The image on the left shows the talotarsal joint in neutral position. When evaluating neutral, simply touch the 4th & 5th metatarsal head/neck and apply enough pressure that the metatarsal heads are perpendicular to the bisection of the leg. The image on the right shows maximum pronation of the entire talotarsal joint complex.



NOTE: When evaluating talotarsal range of motion make sure to “cup” the back of the heel of the foot you are about to test with the same hand as the foot you are testing (if you are evaluating the right foot, use your right hand to “cup” the right heel). Use the opposite hand to maximally pronate the talotarsal joint by loading the 4th & 5th metatarsal heads.

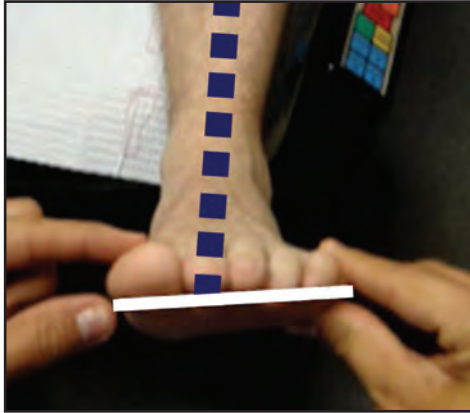


CAUTION: Many physicians only cup the calcaneus and invert/evert the heel.— This only evaluates the posterior facet, representative of one of the four talotarsal joint articulations. This may lead to “missing” a transverse plane dominant condition. There should only be a “slight” amount of talotarsal joint pronation = 3 to 4 degrees.

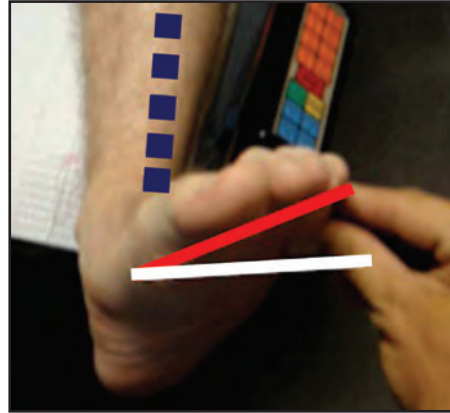
Observe the position of the calcaneus to make sure the patient doesn't have a calcaneal varus deformity.

>> *TaloTarsal Joint Range of Motion (continued)*

Below is an example of another patient who exhibits excessive talotarsal motion (talotarsal displacement/partial dislocation); there is more than a slight amount of talotarsal pronation. This is a clue that the patient has a partial talotarsal displacement.




Talotarsal Neutral Position




Talotarsal Dislocation

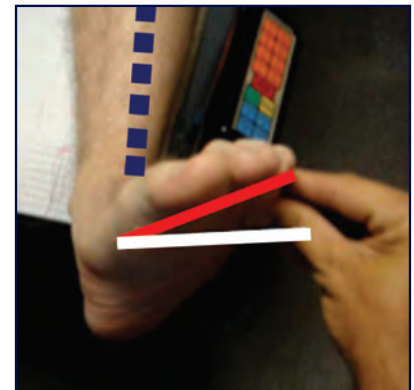
It can be helpful to first demonstrate the normal amount of talotarsal motion and then the patient's excessive motion.



Talotarsal Neutral Position



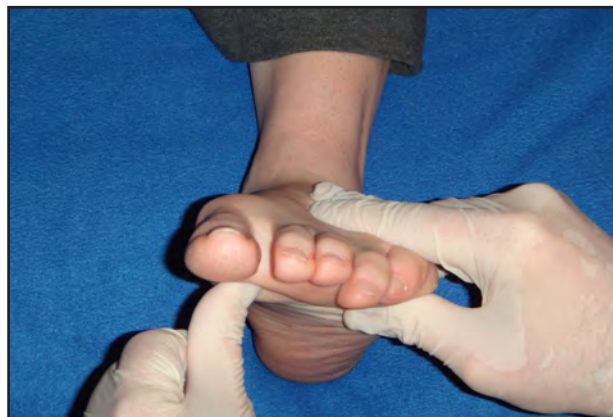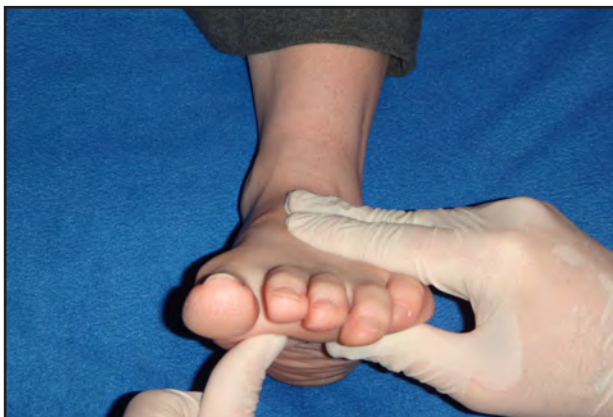Normal Maximum Pronation



Talotarsal Displacement

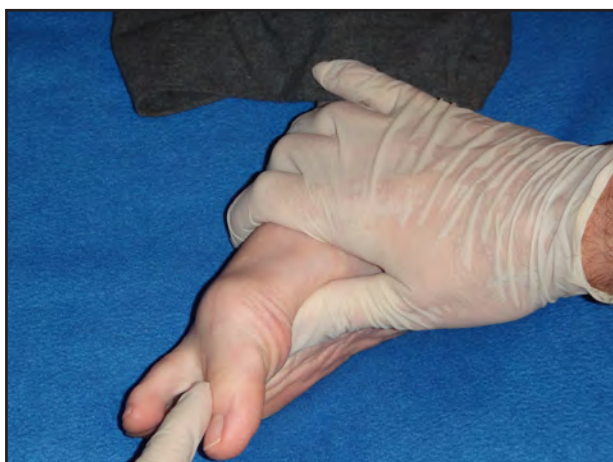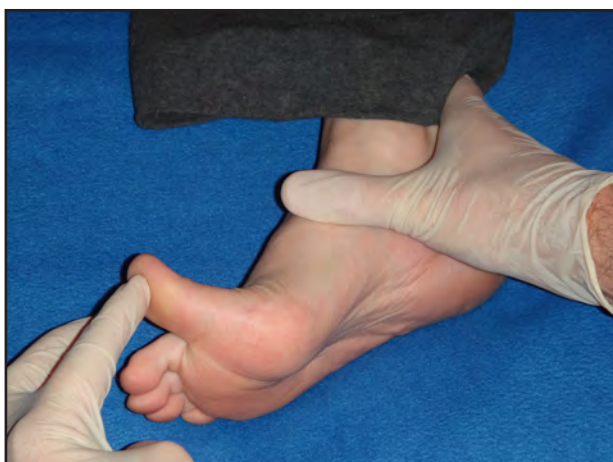>> *Evaluate the 1st Metatarsal Medial Cuneiform Joint/
1st Ray Range of Motion*

The first metatarsal-medial cuneiform joint (first ray) should only have 1 - 2 centimeters of motion. If the patient has excessive motion (hyperextension), it should be identified and appropriately addressed with an orthosis or stabilizing/corrective surgical procedure.



>> *Evaluate the 1st Metatarsal Phalangeal Joint*


The presence or absence of 1st MPJ motion will have an effect on the overall mechanics of the foot. Limited motion at the 1st MPJ leads to an abducted gait pattern.



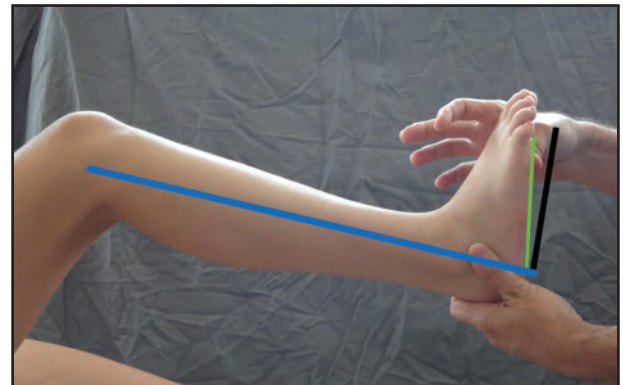
>> Achilles Tendon Testing – Equinus

Equinus often co-exists with talotarsal displacement. In order to select the best course of care, the Achilles tendon should also be tested. When an examiner forcefully and quickly dorsiflexes the foot to check the amount of ankle joint dorsiflexion, this triggers the golgi tendon organs (neurotendinous spindles) which are located at the muscle-tendon junctions, forcing contraction of the gastrosoleal muscles. This produces a reflex plantarflexion, which can lead the examiner to a false-positive finding of an equinus deformity.

>> Passive Dorsiflexion Test



Load 4th & 5th metatarsal heads with knees straight: 0 degrees or more – no lengthening required; no dorsiflexion is available – may require lengthening

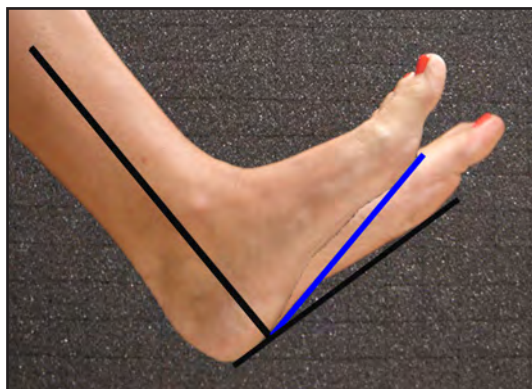


Load 4th & 5th metatarsal heads with knees flexed: 0 degrees or more – no lengthening required; no dorsiflexion is available – may require lengthening

Make sure to apply a slow steady force. Please note that the golgi tendon organs are very sensitive and they will still send the neurotransmission to trigger the reflex mechanism, causing contraction of the GastroSoleal muscles bellies.

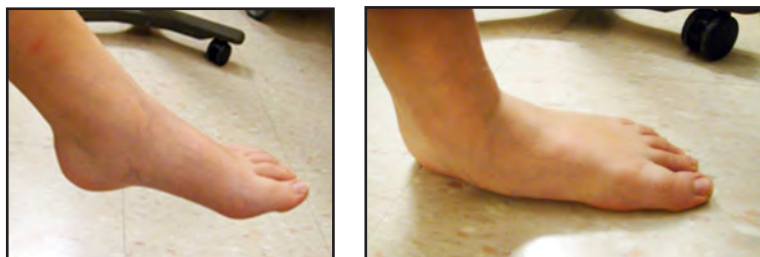If you can get the foot close to 90-degrees to the leg, then no additional surgical lengthening procedures will be necessary, unless there is a significantly lower than normal calcaneal inclination angle. Compare the amount of ankle joint dorsiflexion with the knee straight and flexed to test both the soleus and the gastrocnemius muscles.

>> Active Dorsiflexion Test



A better method to test for equinus is to have the patient actively dorsiflex their ankle with their knee straight and slightly bent. The most important thing we are trying to determine is whether the patient can dorsiflex their forefoot during the swing phase of the gait cycle. One primary benefit of this test is that the active dorsiflexion does not trigger the golgi tendon bodies to give a false positive equinus deformity.

Weightbearing Examination

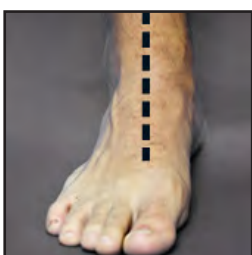

NOTICE THE DIFFERENCE

between non-weightbearing and weightbearing? The talotarsal articular facets are in constant congruent contact when non-weightbearing and partial talotarsal displacement occurs upon weightbearing, leading to a loss of the arch.

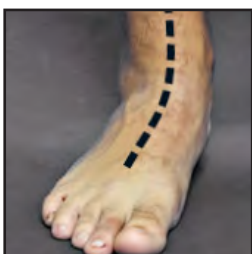>> Frontal View Weightbearing Examination

It is preferred that you first place the talotarsal joint into neutral position:



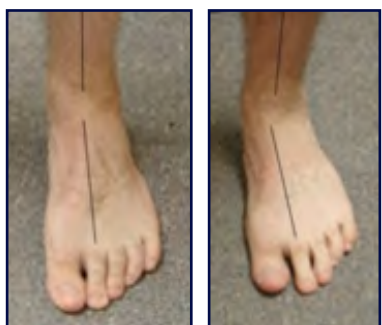This is neutral position –
The articular facets of the talotarsal mechanism are in constant congruent contact. A slight amount of pronation is acceptable.

The patient is then told to relax their foot – relaxed stance position.



The talus then slides off the calcaneus which may lead to a lowering of the arch of the foot (if the navicular drops).

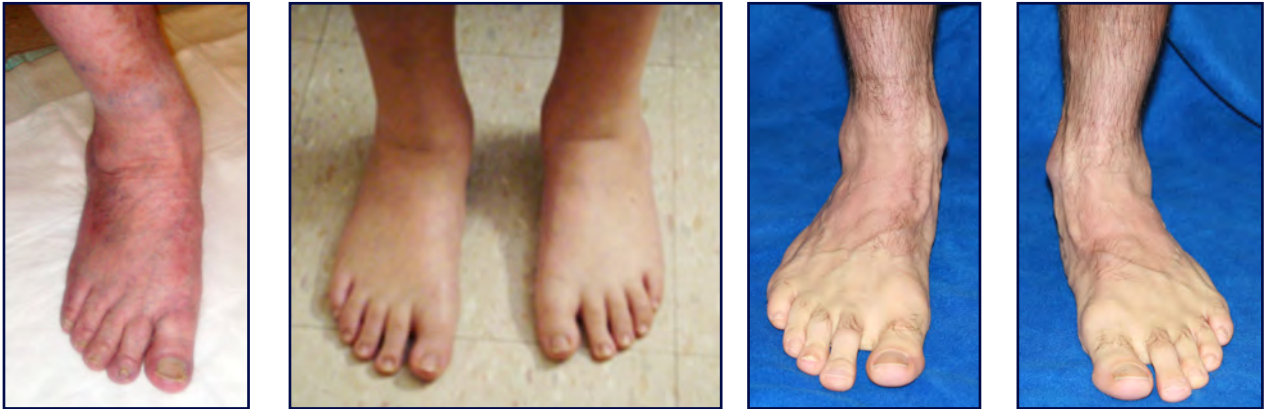This foot exhibits a partial talotarsal displacement deformity.



Here is another comparison of neutral stance to relaxed stance position. Though less acute, this patient still exhibits evidence of partial talotarsal displacement. The finding should be confirmed by radiographic comparison.



NOTE: With the patient's foot in neutral position, point out that this is where their foot "*should be,*" then, as they relax their hindfoot and the talus slips off the calcaneus, they will feel the difference and note that *their foot is now out-of-alignment.*



Compare neutral position to relaxed stance position one foot at a time. Typically, the patient will have to really invert their forefoot to realign their hindfoot. Most patients' 1st metatarsal will be off the ground, but you should be able to gently push the 1st metatarsal back onto the ground.

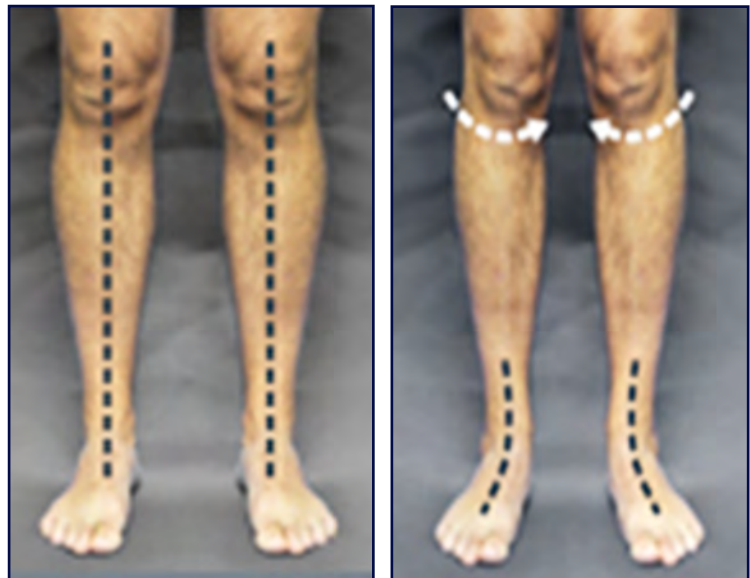
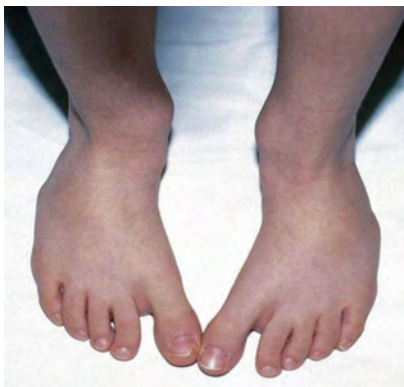
NOTE: Maximum talotarsal dislocation occurs in the unilateral mid-stance phase of the gait cycle, **NOT** when the patient is standing on both feet. Even when there doesn't appear to be much of a deformity on static weightbearing exam, it becomes very visible upon gait analysis.



WARNING: If the patient cannot put their hindfoot back into neutral position – this is a sign that they may have a tarsal coalition or a non-flexible talotarsal displacement deformity.

Be on the look-out for a metatarsus adductus deformity.



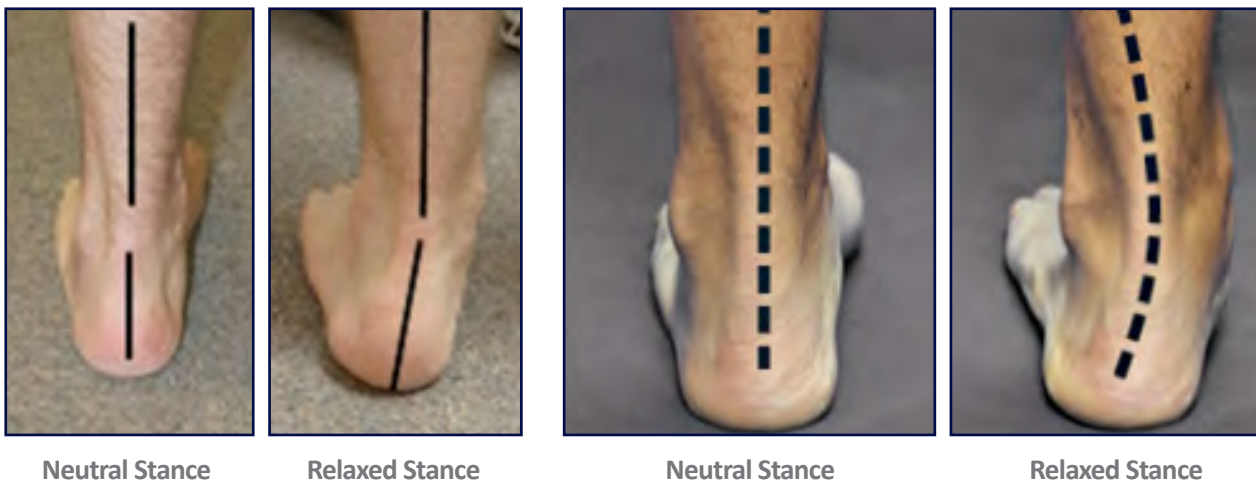
KNEES: Look at the patella while the talotarsal joint is in alignment (neutral stance position), then watch as the talotarsal joint transitions to relaxed stance position and the patella/knees turn inward.



NOTE: Place the patient's foot into neutral position and ask them to focus on their knee, hip and back as the foot collapses during relaxed stance position. This brings the rest of the musculoskeletal chain into the patient's mind and helps them understand that the alignment of their feet can affect their entire body.

>> *Posterior View Weightbearing Examination*

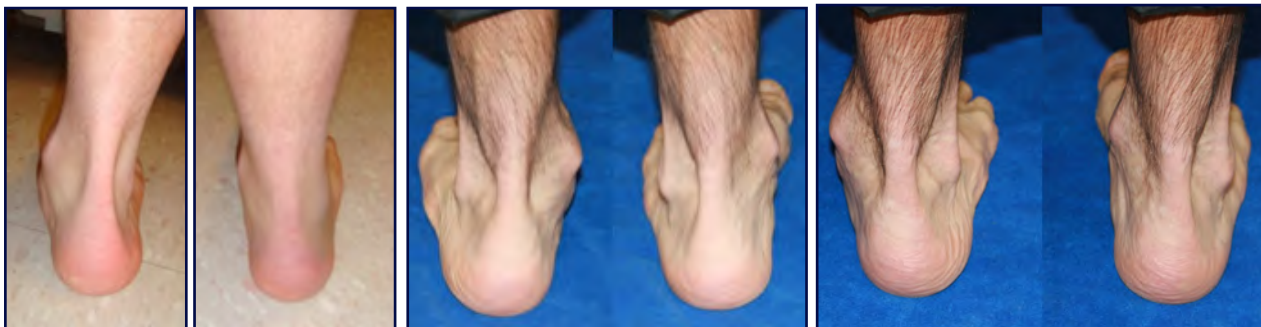Once you have completed a frontal view evaluation, have the patient turn around to evaluate them posteriorly, primarily to observe the heel to leg alignment.



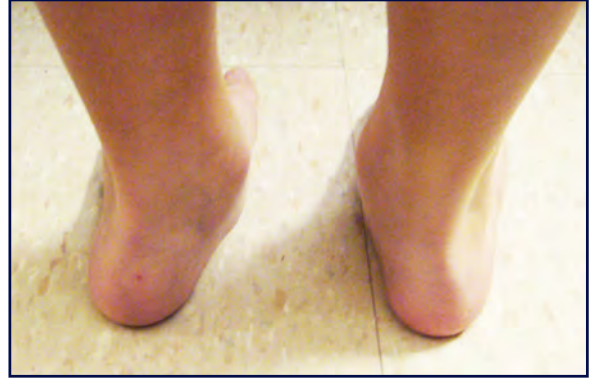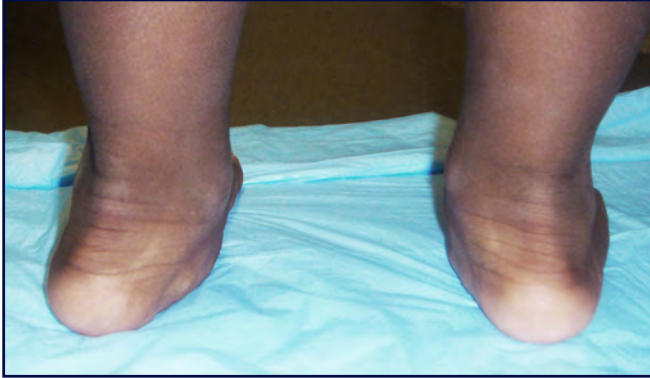The talus is placed into neutral stance position. Notice the alignment of the lower leg with the bisection of the calcaneus.

The following images provide the clues that the primary deformity is talotarsal displacement with a flexible, reducible deformity.

Can you tell which foot is in neutral-balanced talar tarsal stance position and which foot exhibits a partial talotarsal dislocation?



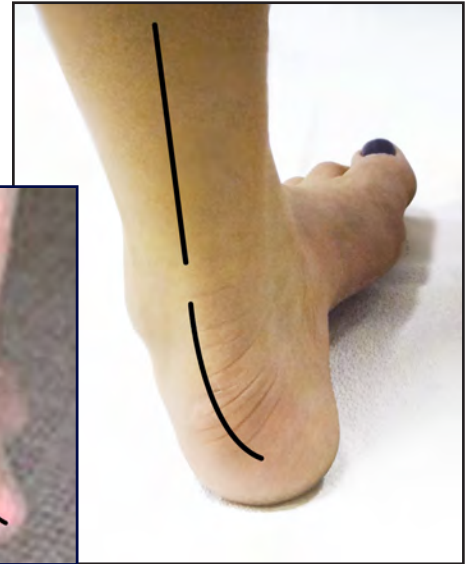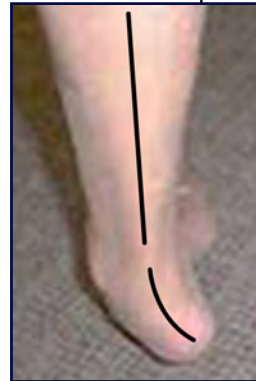It is important to make sure the valgus deformity is, in fact, flexible.



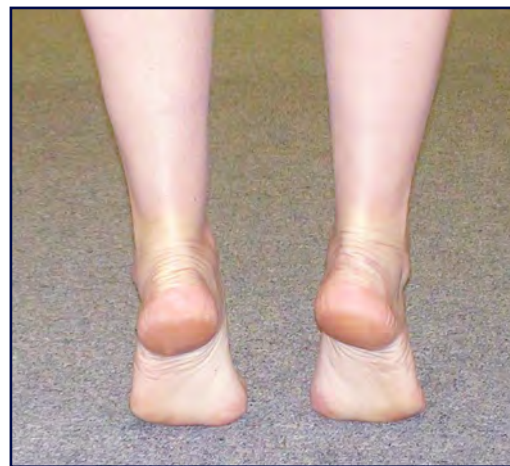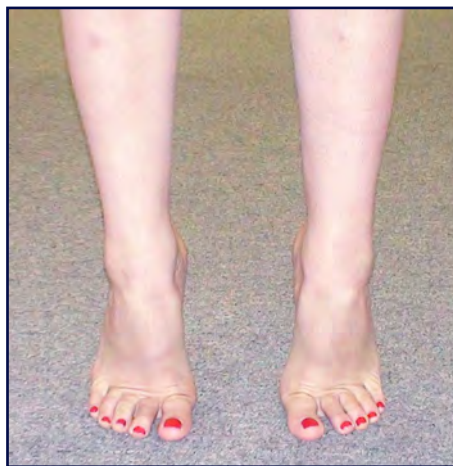CAUTION: be on the look-out for a calcaneal varus deformity.



NOTE: If the patient has a stage 1 or greater posterior tibial tendon dysfunction, the patient may not be able to realign their talotarsal joint. Depending on the severity, this could be an indication that the patient will need a tendon augmentation procedure.



>> Heel-Raise Test



Have the patient stand on the ball of each foot. Observe the back of their heel to see if it returns from a valgus position to rectus or slightly varus alignment. This maneuver also shows the flexibility of the talotarsal joint as the talus becomes reoriented on the calcaneus and therefore reduces the valgus calcaneal alignment.

Gait Analysis

It is recommended to have the spouse, a family member or a friend come out along to watch the gait analysis.

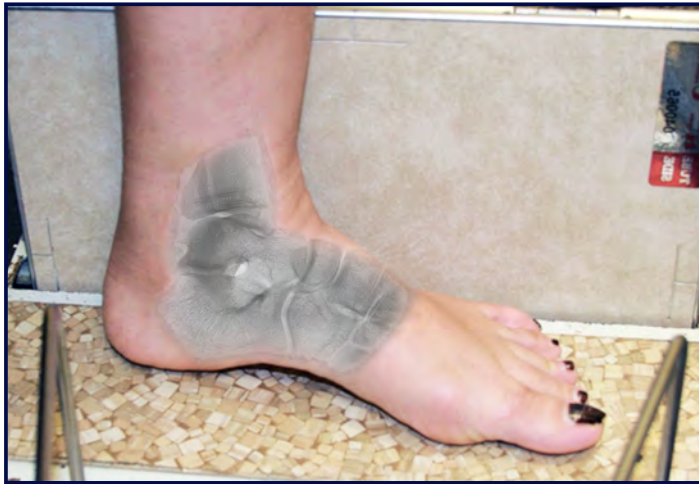With the patient walking away from you, look for the following:					
Shoulders	Back	Hips/Pelvis	Knees	Calcaneus	Forefoot
<input type="checkbox"/> Even	<input type="checkbox"/> Rectus	<input type="checkbox"/> Level	<input type="checkbox"/> Rectus	<input type="checkbox"/> Rectus in Swing	<input type="checkbox"/> Rectus
<input type="checkbox"/> Uneven	<input type="checkbox"/> Curved	<input type="checkbox"/> Uneven	<input type="checkbox"/> Valgus	<input type="checkbox"/> Rectus at Heel Strike	<input type="checkbox"/> Abducted <i>(Too Many Toes Sign)</i>
			<input type="checkbox"/> Varus	<input type="checkbox"/> Valgus at Early Mid-STANCE	<input type="checkbox"/> Adducted
				<input type="checkbox"/> Rectus at Late Mid-STANCE	

With the patient walking towards you, look for the following:					
Shoulders	Back	Hips/Pelvis	Knees	Arch Height	Forefoot
<input type="checkbox"/> Even	<input type="checkbox"/> Rectus	<input type="checkbox"/> Level	<input type="checkbox"/> Rectus	Heel Strike:	<input type="checkbox"/> Rectus
<input type="checkbox"/> Uneven	<input type="checkbox"/> Curved	<input type="checkbox"/> Uneven	<input type="checkbox"/> Valgus	<input type="checkbox"/> Low <input type="checkbox"/> Normal <input type="checkbox"/> High	<input type="checkbox"/> Abducted <i>(Too Many Toes Sign)</i>
			<input type="checkbox"/> Varus	Early Mid-STANCE:	<input type="checkbox"/> Adducted
				<input type="checkbox"/> Low <input type="checkbox"/> Normal <input type="checkbox"/> High	
				Late Mid-STANCE:	
				<input type="checkbox"/> Low <input type="checkbox"/> Normal <input type="checkbox"/> High	
				Heel Lift:	
				<input type="checkbox"/> Low <input type="checkbox"/> Normal <input type="checkbox"/> High	

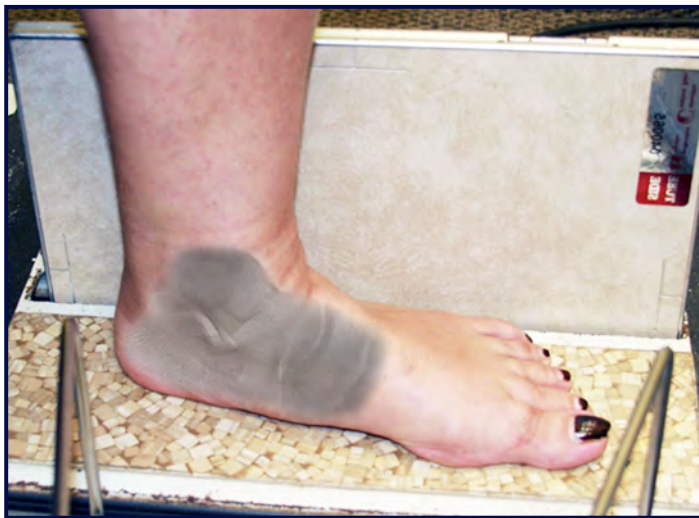Weightbearing Radiographs Evaluation

It is strongly recommended that you order comparison x-rays with the hindfoot in **Neutral and Relaxed Stance** positions, in BOTH DP and Lateral views.

Neutral Stance



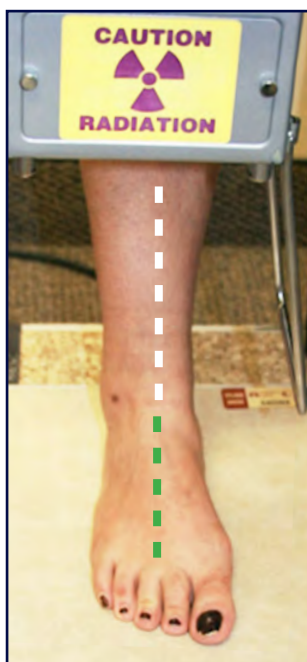Relaxed Stance



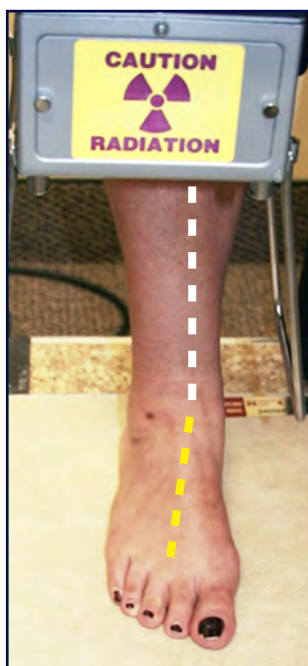These comparative radiographs serve many purposes: they document the deformity, demonstrate the reducibility of the deformity and can provide a clue if a coalition is present (in which case a CT scan should be ordered).

Weightbearing Fluoroscopy is the preferred diagnostic tool. This enables patients to see the pathologic osseous motion in action, which helps drive home the need for corrective action.

>> DP Positioning

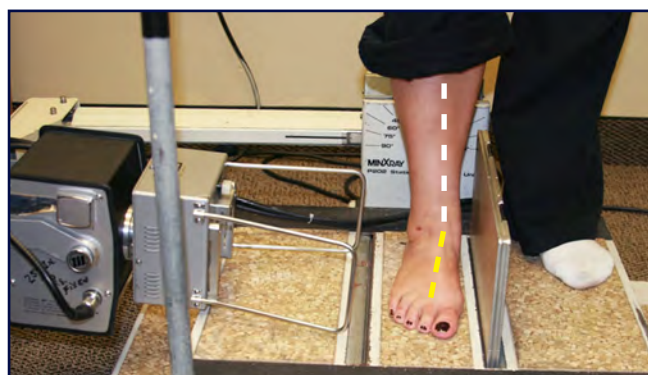

Neutral Stance Position

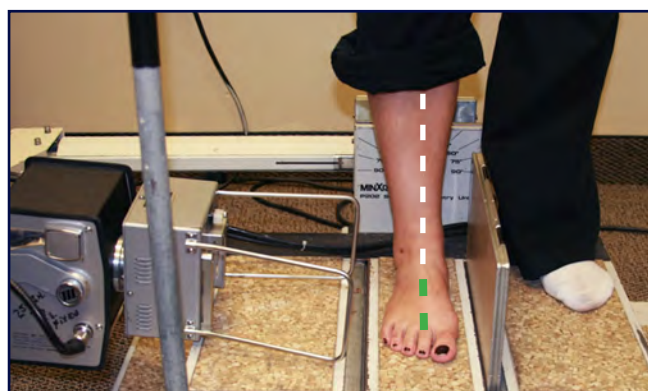

Relaxed Stance Position

>> Lateral Positioning



Relaxed Stance Position



Neutral Stance Position

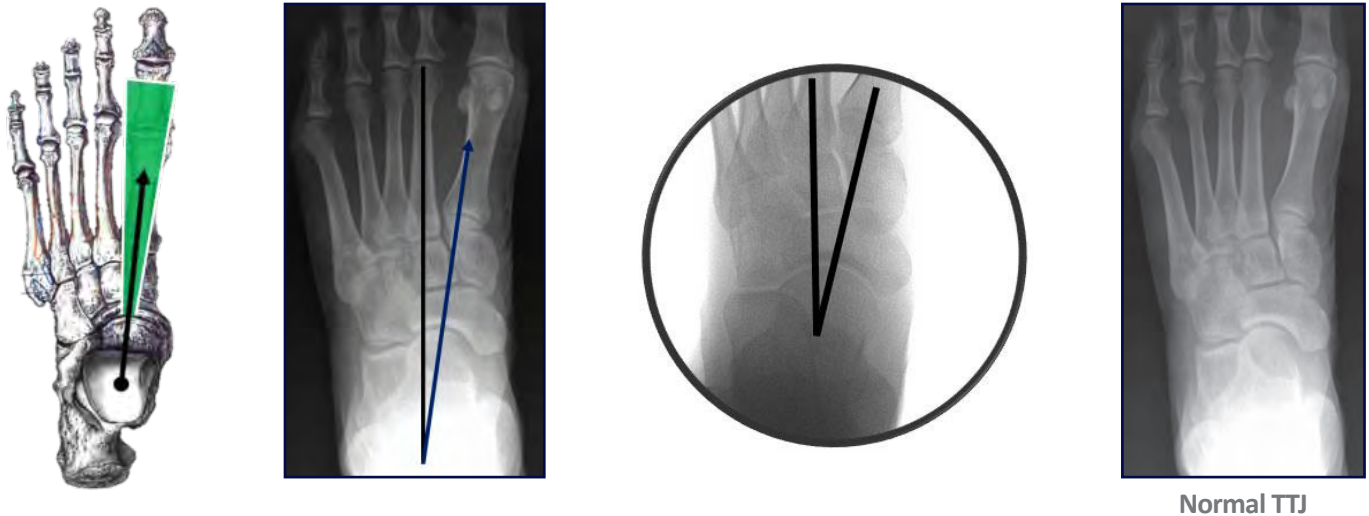
Dorsoplantar (DP) View

- The DP view shows if a transverse plane deformity is present.
- The bisection of the talus should be between 0 and 16 degrees from the 2nd metatarsal.

Weightbearing DP View - Transverse Plane Dislocation Deformity	
Ideal Talar 2nd Metatarsal (T2M) Angle:	
Aligned TTJ/NP	3-6 degrees
Relaxed Stance Position (RSP) NORMAL	< 16 degrees
Relaxed Stance Position (RSP) ABNORMAL	> 16 degrees

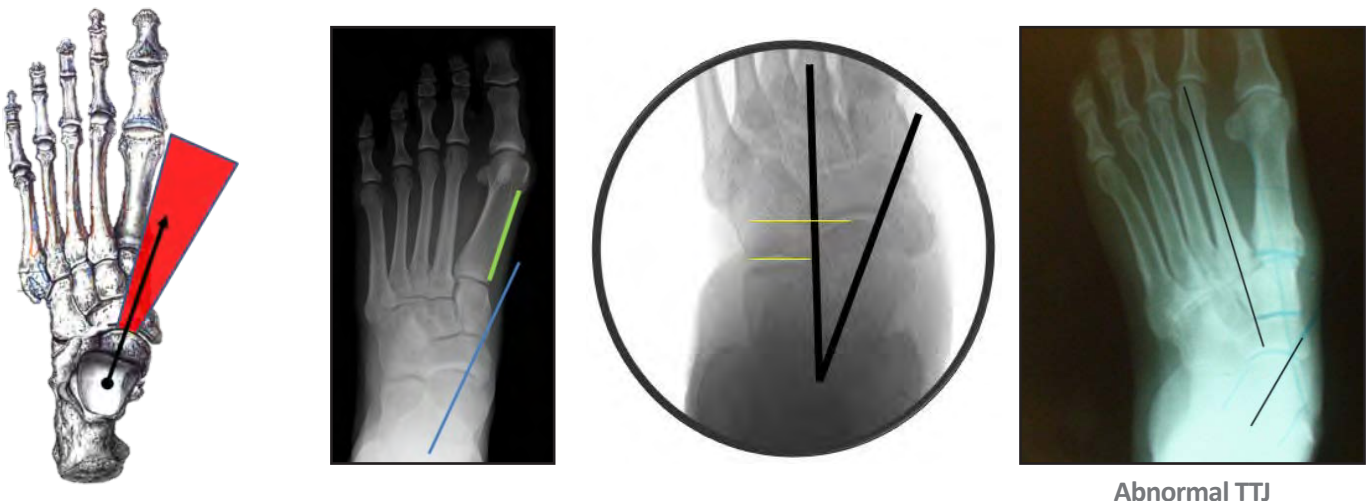
NORMAL = Talotarsal Joint Alignment:

The quick way to determine normal or abnormal is if the bisection of the talus is medial to the medial aspect of the 1st metatarsal shaft.

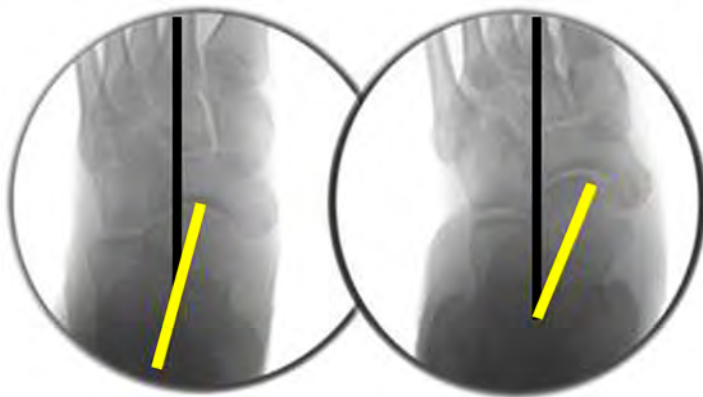


ABNORMAL = Partial TaloTarsal Joint Dislocation

A talar second metatarsal angle > 16 is evidence of a talotarsal dislocation. If the bisection of the talus falls medial to the medial aspect of the 1st metatarsal, then a transverse plane talotarsal dislocation deformity exists.

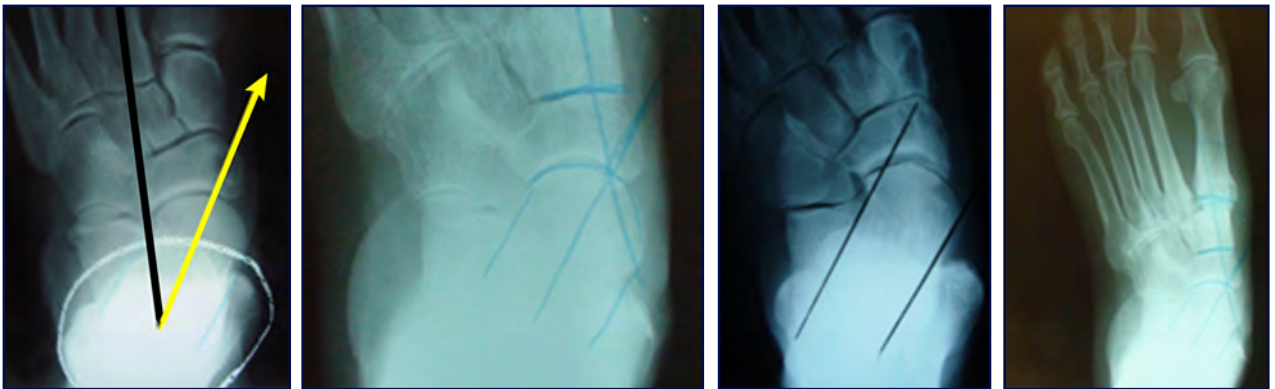


>> Comparison view:

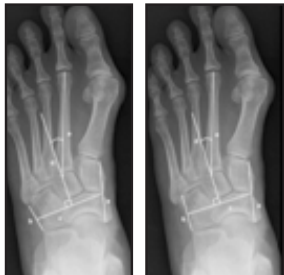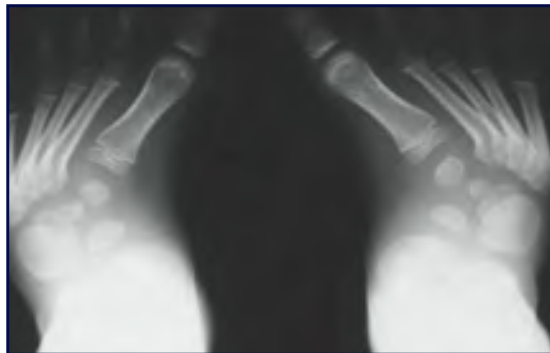
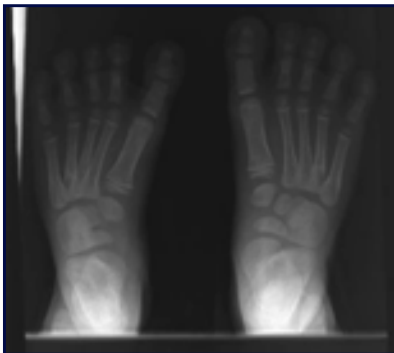

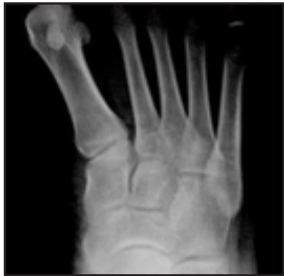
Comparison of AP/DP x-rays with the talar second metatarsal (T2M) angle drawn.

Neutral stance position shows < 16 degree angle whereas the resting stance position T2M angle is > 16 degrees. Also, notice the anterior displacement of the talus.








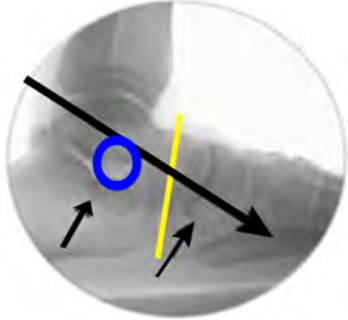

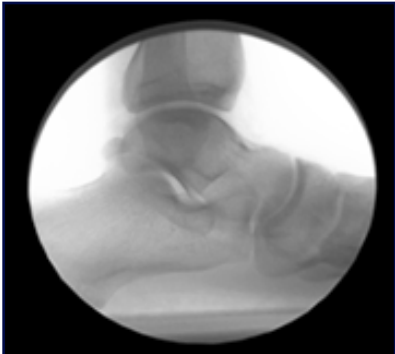
⚠ CAUTION: Be on the look-out for Metatarsus Primus Varus and Metatarsus Adductus.



Lateral View

The lateral x-ray shows **sagittal and frontal plane deformity(ies)**.

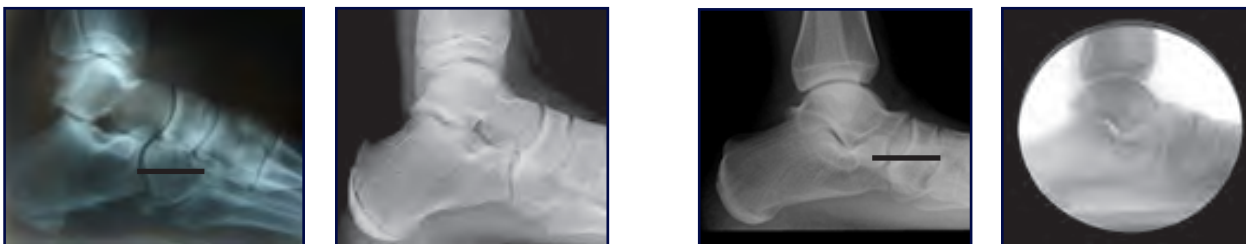The bisection of the talus should fall within the shaft of the 1st metatarsal. If the bisection is more acute or falls below the 1st metatarsal, then a sagittal plane deformity exists. Talar declination angle > 21 is considered abnormal.

Compare	Normal	Abnormal
<ul style="list-style-type: none"> • Open/closed sinus tarsi • Anterior displacement of the talus by an anterior break in the cyma line • Navicular drop • Calcaneal inclination angle • Think about the sustentaculum tali • Signs of a tarsal coalition 	   	   

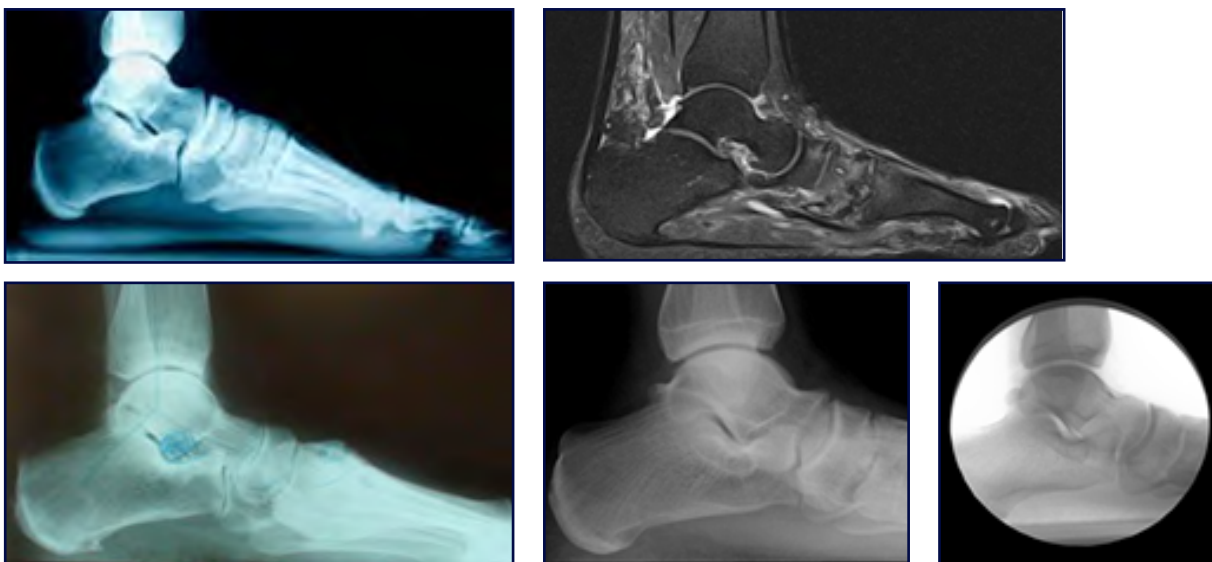
>> *Navicular Position In Regard To The Cuboid*


The navicular should overlap on the dorsal third of the cuboid when the talotarsal joint is in alignment.

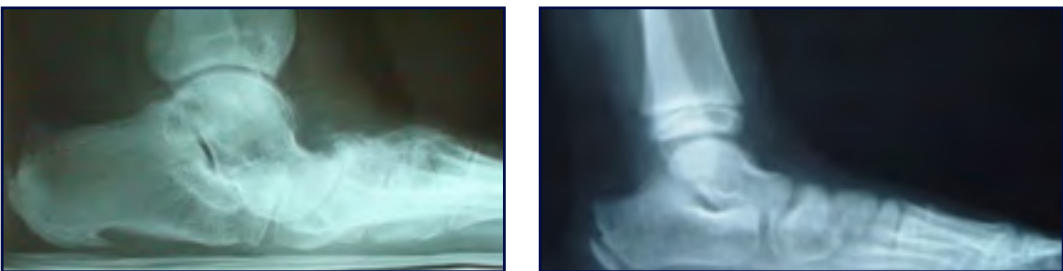Notice the navicular drop below the horizontal bisection of the cuboid on these resting stance position x-rays. This is further evidence of a talotarsal joint dislocation.



Calcaneal Inclination Angle (CIA) – EOTTS has no/minimal effect on the calcaneal pitch angle.

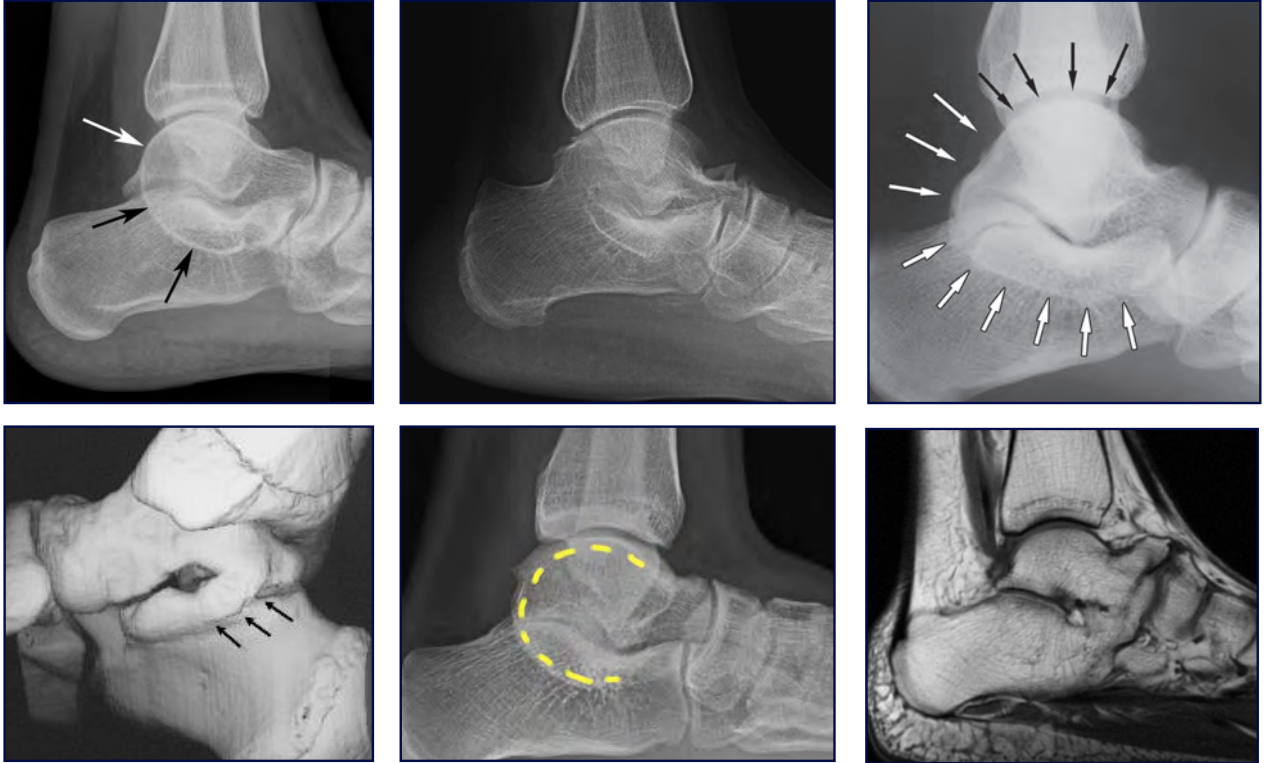


 **NOTE:** If the CIA is lower than normal – the patient may benefit from a gastro-soleal or tendoachilles lengthening and/or calcaneal slide osteotomy, if indicated.





CAUTION: Be on the look-out for a tarsal coalition - the best/easiest way is to look at comparison radiographs.



If you suspect a tarsal coalition – order a CT scan.

Talocalcaneal:

Fuses between the ages of 12 – 16 years old
Usually the middle facet
Halo sign - may be observed on lateral x-ray

Calcaneonavicular:

Fuses between 8 – 12 years old
Medial oblique foot x-ray shows narrowing/ossification
Calcaneal beak/anteater sign

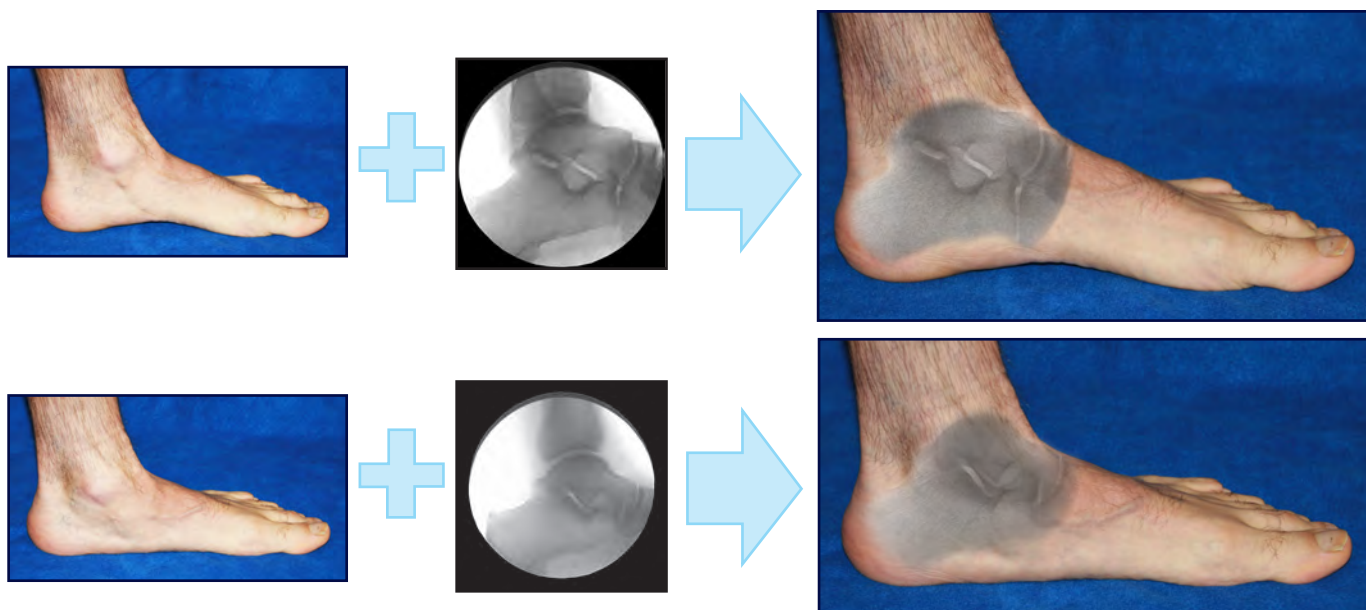
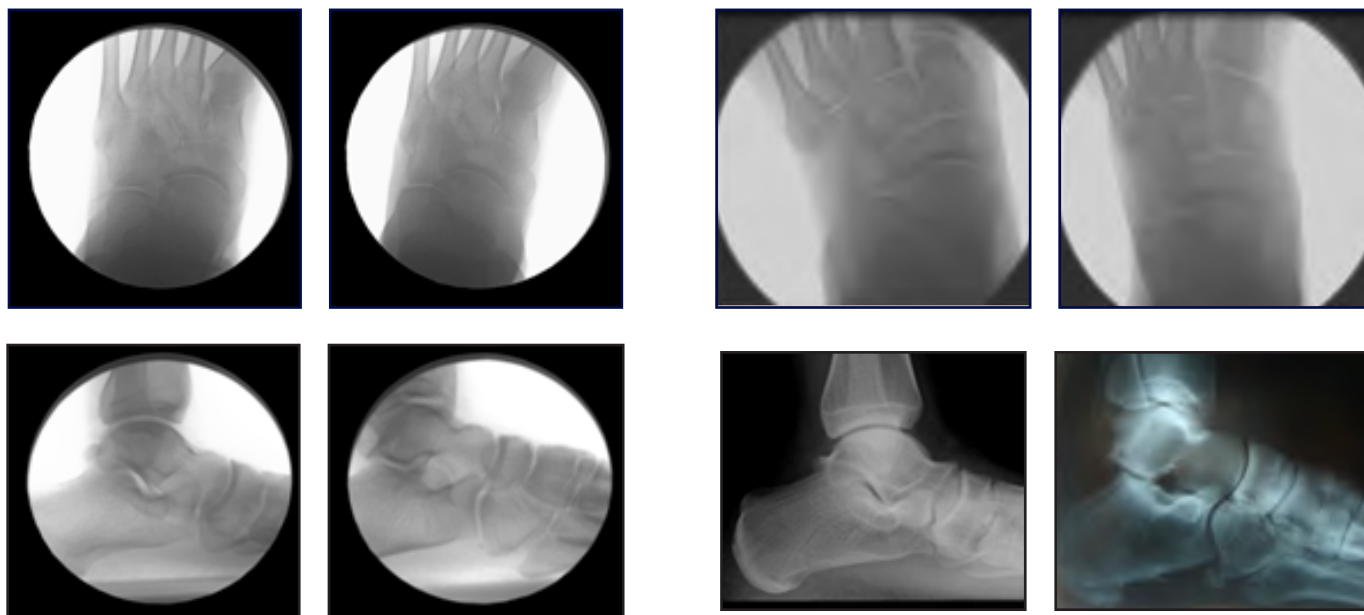
X-Ray Comparison Views

Comparative x-rays examining the foot structure presentation in both neutral position and in relaxed stance position are extremely useful to:

- Diagnose the patient
- Ensure the patient is a candidate for an EOTTS procedure
- Rule out concomitant deformities

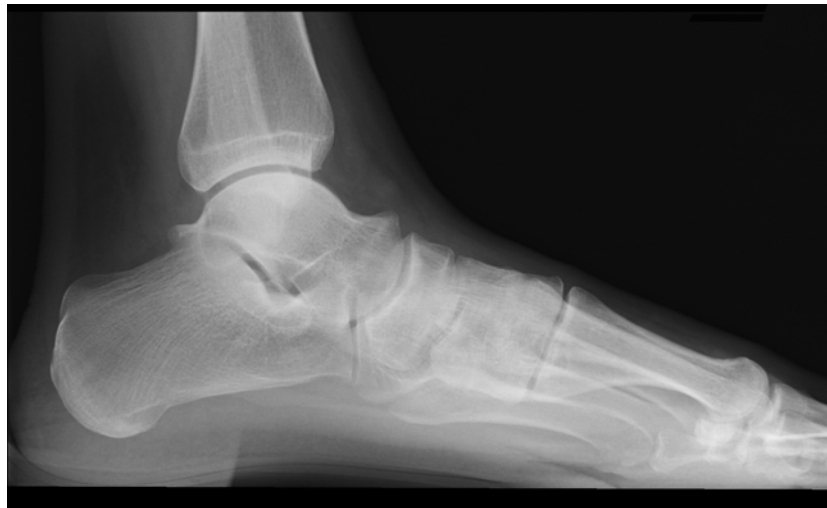
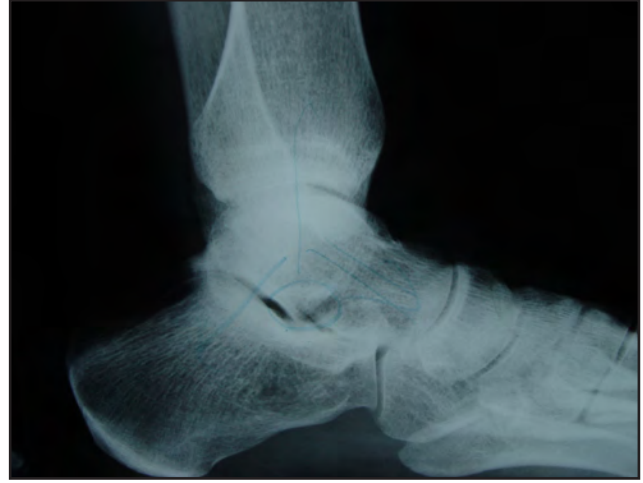
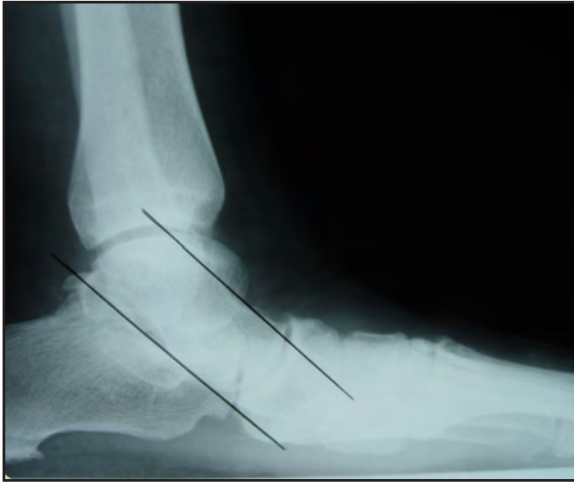Can you tell which views are neutral position and which are **relaxed stance position**?





How can you determine if the deformity is rigid or non-flexible?



That's why it's important to take comparison films. With a rigid deformity, you can't tell which image is neutral or relaxed stance, they both look the same.

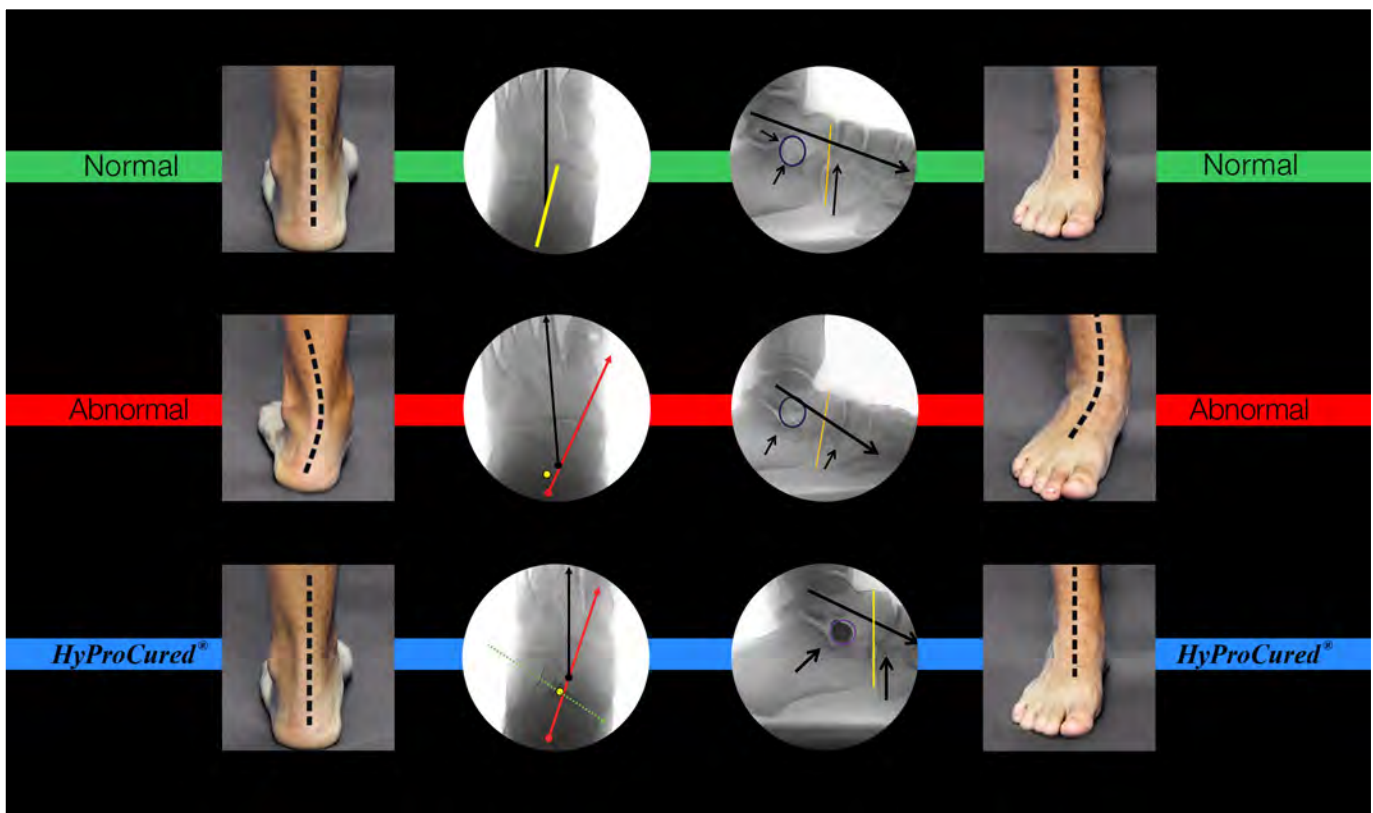
Reviewing X-Rays With Patient

It's Important to Emphasize:

DP View	Talar bisection in relation to the 1st metatarsal - transverse plane deformity
Lateral View	<ul style="list-style-type: none"> • Open vs. obliterated sinus tarsi • Cyma line • Navicular drop • Calcaneal inclination angle/calcaneal pitch



HINT: Make sure that when you discuss x-rays with the patient that you use the “Normal – Abnormal – *HyProCured*®” exam room poster.



Patient Selection: Indications & Contra-Indications

Inappropriate patient selection for the ETTOS procedure can lead to compromised or less than desirable results. The patient must have a flexible, reducible, talotarsal joint. If the talus cannot be repositioned onto the tarsal bones (calcaneus/navicular), then it is possible there is a tarsal coalition, severe arthritic changes or an end-stage deformity. If the sinus tarsi cannot be “re-opened,” then EOTTS with *HyProCure*® should not be performed. The exception to the rule is when the patient has an identified tarsal coalition that will be resected.

It is strongly recommended that the surgeon order comparison x-rays of RSP and NSP to demonstrate the presence of reducibility of the deformity. This also helps to rule out the presence of a tarsal coalition. If there is any suspicion of a coalition, other imaging studies should be ordered.

This comparison can be used as part of the presentation to the patient, demonstrating the ideal talar position compared to how the talus is displacing on the tarsal mechanism when the patient applies weight to their foot.

Important considerations:

- Flexibility/reducibility/severity of the talotarsal displacement
- Calcaneal inclination angle
- Restoration of navicular position – lateral x-ray
- Integrity of the posterior tibial tendon
- Stability of the 1st metatarsal medial cuneiform joint
- Range of motion of the 1st MPJ
- Equinus (?)

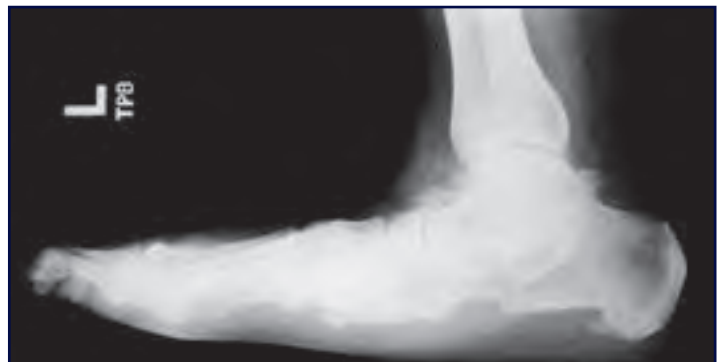
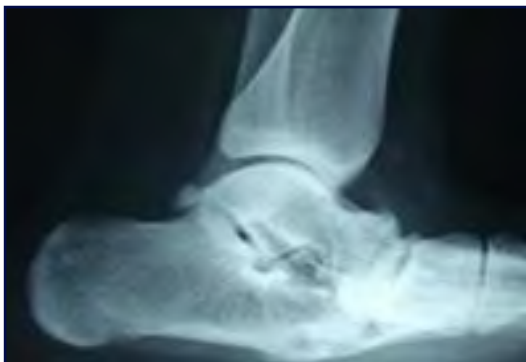>> *Absolute Contra-Indications*



There are limitations and exclusions to every surgical procedure.

Children three-years-old and younger – this is because the osseous chamber forming the sinus tarsi has not developed and there is possible risk to the cartilaginous tissue forming into bone.

Completely rigid/fixed talotarsal joint – however, the exception is when there is a tarsal coalition that has been identified and successfully resected, allowing for a recurrently displacing talotarsal mechanism which could potentially be treated with EOTTS using *HyProCure*.





CAUTION: If the patient's talotarsal joint is semi-flexible/semi-reducible, then the chance of failure will increase 50% (this is a non-evidenced-based estimate). A semi-flexible talotarsal joint is not a contra-indication, but definitely will increase the chance of possible failure.

Arthritis is not a contra-indication simply because arthritis is a disease of a joint. An EOTTS device is not inserted into a joint, but rather into an osseous chamber. Arthritis would only be a factor if it was so destructive within one or more of the talotarsal articulations that the disease process eliminated joint motion.

An EOTTS device should not lead to arthritis of a talotarsal joint articulation; rather it will reduce the likelihood of arthritis because stabilization of the talotarsal joint leads to decreased strain. Conversely, what will happen to the talotarsal joint if it isn't stabilized? There will be an increased chance of arthritis.

IDEAL CANDIDATE

The ideal candidate for an EOTTS procedure is an individual older than three years of age with a flexible/reducible talotarsal joint dislocation deformity.

BE ON THE LOOKOUT FOR SECONDARY DEFORMITIES!

Many times there are co-deformities that may or may not need conservative or surgical management, but the failure to identify or address these co-deformities could lead to less than acceptable results or to failure of the EOTTS procedure.

The extent of the talotarsal dislocation deformity is a very important consideration. A good comparison is a neck osteotomy when performing hallux valgus/metatarsus primus varus deformity correction; it is only going to work if the intermetatarsal angle is less than 16 degrees. There are clear established guidelines when it comes to metatarsal surgery, but there are no clear standards when it comes to the insertion of a sinus tarsi implant. The best advice comes from radiographic correction demonstrated in an EOTTS Retrospective Study¹ that evaluated 95 feet undergoing EOTTS with HyProCure® as a stand-alone procedure. The findings of this paper help to establish the amount of correction achieved. However, the ultimate correction depends on the size of the stent.

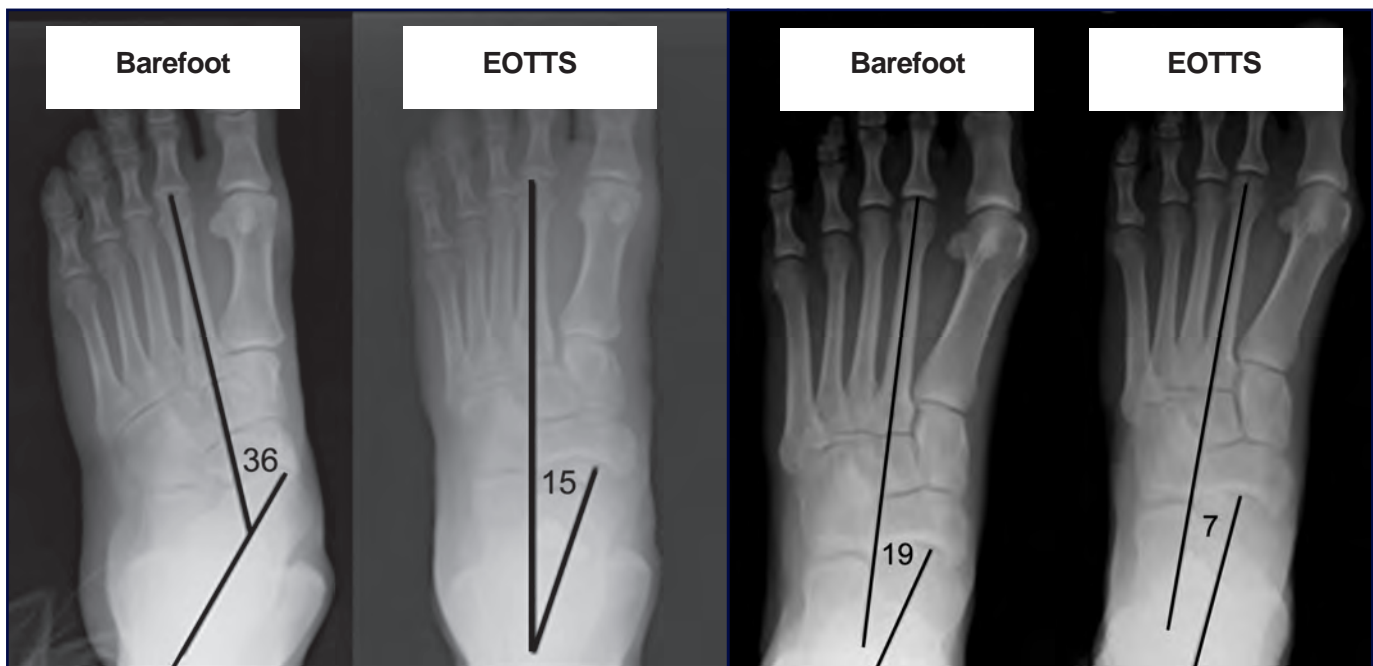
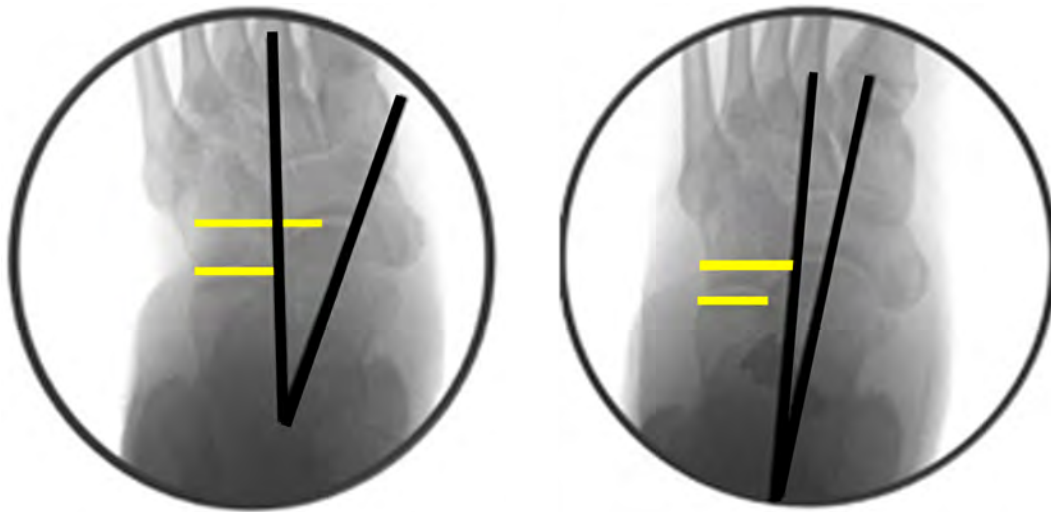
¹ Graham ME, Jawrani NT, Chikka A, Rogers R: Surgical Treatment of Hyperpronation Using an Extraosseous Talotarsal Stabilization Device: Radiographic Outcomes in 70 Adult Patients. J Foot Ankle Surg.51(5):548-555, 2012

EOTTS - Transverse Plane Correction (Talar Second Metatarsal Angle)

The **AVERAGE** reduction in the transverse plane was 19 degrees.

The **MAXIMUM** correction achieved was 37 degrees.

The end range of deformity > 45 degrees was only corrected to 31 degrees (which is still better than an orthotic-arch support)

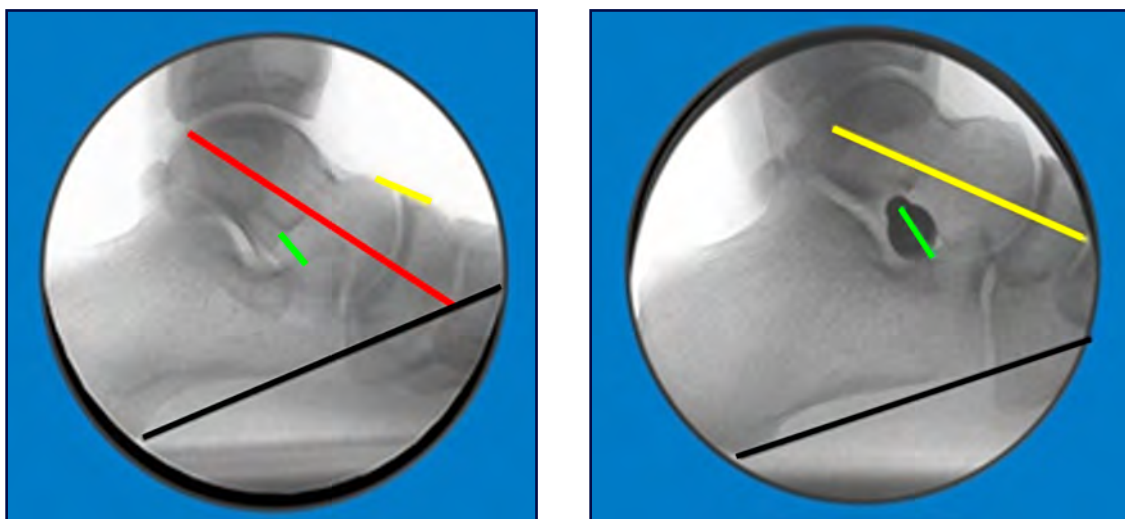


EOTTS - Sagittal Plane Correction (Talar Declination Angle)

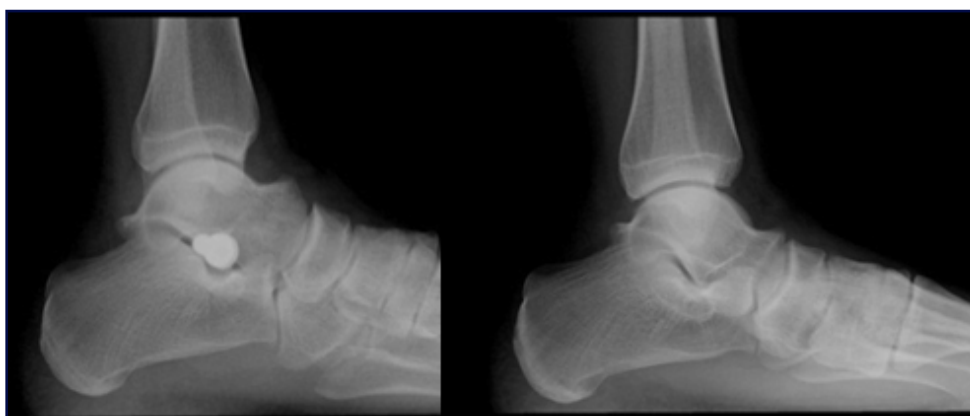The **AVERAGE** correction was 7 degrees.

The **GREATEST** reduction was 19 degrees.

There were no “over-corrections.”



>> Other Important Points to Consider



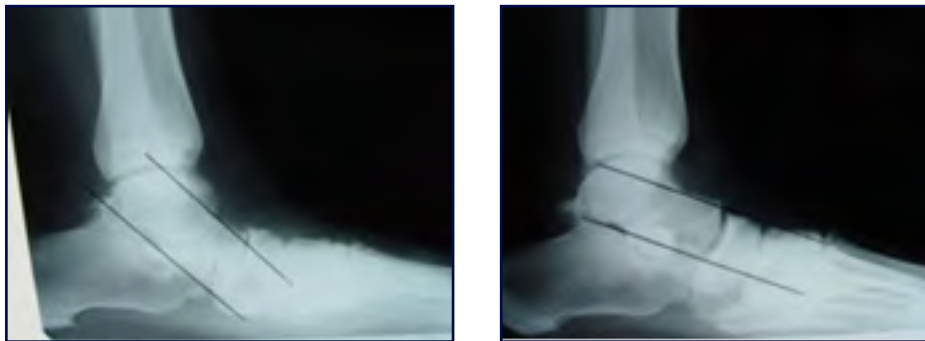
- 1. EOTTS has minimal to no effect on the calcaneal inclination angle/pitch angle.**

If a patient has a lower than normal calcaneal inclination angle, it is possible that they will need adjunct procedures to address that particular deformity.

2. The strength of the posterior tibial tendon must be taken into consideration and specifically the position of the navicular.

Navicular position determines the strain placed on the posterior tibial tendon:

- **GRADE 1** (tendon is still intact, no significant damage) posterior tibial tendon dysfunction should resolve with the realignment of the talotarsal joint.
- **GRADE 2A** (tendon is still intact) may require tendon augmentation.
- **GRADE 2B** indicates significant tendon pathology that could require tendon augmentation and osseous mid-foot reconstruction as well as EOTTS.
- **GRADE 3** tendon dysfunction is not a candidate for EOTTS as there will be a severe talotarsal displacement, this patient typically requires a triple arthrodesis.



3. The stability of the 1st ray is also a very critical factor.

Hypermobility/instability of the first metatarsocuneiform joint will lead to instability in the medial column of the foot. This must be evaluated and, depending on the degree of instability, will determine the need to address the excessive motion. A mild to moderate elevation could respond to an arch support, whereas a moderate to severe deformity may require an arthrodesis of the first metatarsal cuneiform joint.

4. Range of motion of the 1st metatarsophalangeal joint (MPJ).

A lack of motion within the 1st MPJ will lead to an abducted gait. Every option should be considered to restore, as close as possible, the natural range or motion to the 1st MPJ. A mild-moderate limitation of motion may benefit from a 1st MPJ cut-out, or padded 2-5 metatarsal heads. A moderate to severe deformity may require an arthroplasty or an arthrodesis of the first metatarsal phalangeal joint.

5. Equinus.

The accepted diagnosis of equinus has been defined as a condition where the foot cannot be dorsiflexed beyond a right angle of the axis of the leg.² Care should be taken when testing the flexibility of the Achilles tendon, as discussed in the non-weightbearing examination section, to not produce a false-positive test due to triggering the tendon-golgi body reflex mechanism. If there is a severe contracture, it could be addressed at the same time as the EOTTS procedure or if mild/moderate a lengthening procedure could be staged.

EOTTS Has Its Limitations



REMEMBER the ideal patient is one whose talus is displacing on the calcaneus/navicular and it is possible to reduce the deformity by realigning the articular facets of the talus on the calcaneus/navicular. Typical patients who receive an EOTTS procedure are ones who:

- did not have successful results with conservative care such as arch support/custom-made foot orthoses
- have a dislocation deformity that simply cannot be adequately addressed by conservative measures

Be sure to identify other structural deficiencies within the foot and ankle that should be addressed conservatively or surgically.

Sometimes an EOTTS procedure may be attempted in a less-than-ideal candidate prior to a more aggressive surgical procedure. This may give the patient “enough” correction/talotarsal stability to negate or delay the necessity of the more aggressive reconstruction procedure.

² Walsham, William Johnson and Hughes, William Kent: *The Deformities Of The Human Foot: With Their Treatment.* William Wood & Co., New York, p. 254, 1895.

Diagnosis and Treatment Options

The patient will need time to consider and research their treatment options. To assist in this process:

1. Give them a printed copy of the EOTTS *HyProCure*® brochure.
2. Have them view information on the internet. *(Remember to include information and links on your website.)*
3. Schedule a follow-up appointment to answer any questions.

Sample Script for Patient Discussion/Presentation

The symptoms that you are experiencing (add specifics) begin in your hindfoot.

The ankle bone (talus) is slipping off its normal position on the heel bone. The forces that should pass through the back of your heel are now acting on the inner front of the foot.

Whenever you put weight on your feet, excessive abnormal forces are straining your tissues. This has likely been occurring your entire life; it was only a matter of time before you experienced pain.

Exactly where the pain begins is different for everyone. For some, it begins as growing pain. For others, it's heel pain, tendon pain, knee, hip or back pain.

You can take medications that will mask the pain, or we can try injections and physical therapy, but those excessive forces will still be present, creating further tissue damage.

The real solution to this problem is to stabilize the ankle bone on the heel bone. This will prevent the displacement and rebalance the forces. Immediately, the excessive strain on the tissues will be decreased. Once the surgery heals, you should have immediate pain relief, and over time, even greater relief as the tissues heal. Of course, healing time varies from patient to patient, depending on how much damage has been done.

*The option I prefer to stabilize the ankle bone and realign the foot is insertion of a titanium stent into the sinus tarsi through a very small incision. (Show the patient a foot model with the *HyProCure*® stent.)*



Following the procedure, the normal amount of motion should return. This stent normalizes the foot's motion; it doesn't take away the normal motion. It simply keeps the open space open, as it should be. You don't walk on the stent – the force from the body acts on the joint behind and in front of the stent. There is minimal force acting on the stent itself.

Once the stent is placed, you will be allowed to immediately walk on your foot. However, you should limit the amount of walking for the first several days to around your house. The typical recovery is different from foot to foot and patient to patient. Generally speaking, most patients are back to their normal activities within 4 to 6 weeks. No running is allowed until 6 weeks after the stent is inserted.

After 6 weeks, you are allowed to increase your activity level. You will want to pay attention to your body and let it tell you your limits. Once you have recovered, you should not have any limitation



regarding physical activity – however you may still have some soreness at the surgical site. Also be aware that usually both feet need to be realigned.

There are potential risks associated with this procedure:

- There are no guarantees that this procedure will work - nothing is 100% successful.*
- In approximately 6% of patients, the stent has to be permanently removed*
- There is up to an 8% chance that the stent will have to be repositioned or re-sized*
- Full recovery could take up to a year or longer.*

There are other options – but, in my opinion, none provide the same correction and freedom of lifestyle as the stent. For example, we could try custom orthotics. These have many limitations – when you are not wearing them, they won't work at all.

And you will need shoes that fit the orthotic. The benefit of the sinus tarsi stent is that regardless of whether you are wearing shoes, slippers, high heels or going barefoot – the stent is doing its job to realign your feet.

The other problem with an orthotic is that although it might take some pressure off the arch, it simply cannot prevent the ankle bone from sliding off the heel bone since the ankle bone is above the heel bone. It is possible the arch support can take some pressure off the arch of your foot and provide some short-term relief, but no good long-term results.

You may still need an arch support in addition to the EOTTS procedure and the EOTTS procedure will be more effective with the arch support.

Another option is to perform a traditional reconstructive surgical procedure. In this procedure I would cut and shift your bones and fuse the joints. This involves a long surgery with a prolonged recovery period when you won't be able to walk. Physical therapy will be required and the complications can be more severe. There is also an increased chance that I will have to take you back to surgery to remove plates and screws as well as an increased chance of arthritis in other joints.

I also like the EOTTS procedure because a

substantial amount of good research has been done on the outcomes. The research and the outcomes show better results than any alternatives. I have personally seen many of my patients experience very positive results.

What I want you to do is to go home and think about the options. Here is a brochure on the EOTTS procedure. I advise you to visit their website and do your own research. I want to see you back in one to two weeks to discuss your case and to answer any further questions.

Other Sample Dialogs

>> Heel Pain/Plantar Fasciopathy

The pain in your heel is a symptom. A long, thick, ligament-like structure, called the plantar fascia, is meant to support your inner arch. However, it is being over-stretched while you are standing, walking or running. Due to years of this over-stretching, the ligament has developed partial tears. This ligament tries to heal when you are off your feet or while you are sleeping, but the excessive forces that are causing the over-stretching are still present.

The root of your heel pain is due to the partial dislocation of the ankle bone on the heel bone. Remember when I had you stand and place your foot into the normal alignment, then when you relaxed your foot it collapsed? That collapse increases the strain to the inner band of the plantar fascia.


The difference between the normal ankle bone alignment and an abnormal alignment can be seen by looking at the small natural opening between the ankle bone and the other bones. This space is called the sinus tarsi. In normal alignment, it is always open. In abnormal alignment, the ankle bone slides off the heel and collapses that space. (Refer to the patient's x-rays and compare them to the poster.)

In order to adequately treat your heel pain and provide long-term relief, I need to realign your ankle bone. I can try an arch support, but the arch support cannot stabilize the



NOTE: It's important to use an analogy like a car tire with a small hole – you can tell your patient, “Imagine that your heel pain was like the tire on your car that kept going flat - that is the symptom. The cause of your tire going flat is the small hole in the tire.”

It is important that we fix the reason your tire went flat and not just keep putting air in it. Otherwise the hole will just keep getting bigger and bigger and the air will leak out faster and faster. The ideal way to fix this tire problem is not to just simply continue to put air in the tire, but to first repair the hole then to fill the tire with air. In the same manner, the best solution



to your heel pain is to first stabilize your hindfoot. Immediately this takes the strain off the plantar fascia so that it can heal and you will no longer have pain. Let's talk about the potential risks and complications of this EOTTS procedure...”

ankle bone on top of the heel bone. It may help to prevent some of your arch collapse, but it cannot realign or stabilize your ankle bone.

The method I prefer is to insert a small titanium stent into the collapsed space. This instantly realigns the ankle bone and it will take the strain off the plantar fascia allowing it to heal. How long the healing takes depends on how much damage has occurred and how much scar tissue has developed. Most patients feel a difference right away.



>> Bunions

The problem with your big toe joint actually starts with your hindfoot – because your ankle bone is partially dislocating on the heel bone. The ankle bone unlocks the bones of your mid-foot which weakens the 1st metatarsal, the long bone from the middle of your foot to where your toe starts. The ground pushes up on this bone, forcing it out of alignment.

Your metatarsal bone is actually straight, as is your toe; the real deformity is just that it has become displaced as a result of the excessive hindfoot motion. Most doctors simply cut and shift the 1st metatarsal bone which may seem to fix the problem. However, there is a large recurrence rate because the reason why you developed the bunion in the first place was due to the excessive hindfoot motion and that excessive motion is still present.

Let's think about the steering on your car. If the steering was off and you took your car to the tire shop and they realigned your steering, but then put on your old worn out

tires, your steering might be okay initially. However, very soon it will become misaligned again because your tires are worn out which throws your steering out of alignment all over again. The real solution is to realign the steering and put new balanced tires on your car.

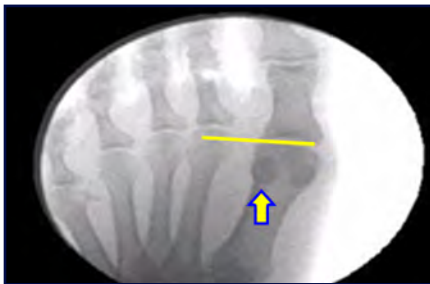In the same manner, the real solution to your bunion deformity is to first realign your hindfoot by inserting a small titanium stent into the collapsed space in between your ankle and heel bones.



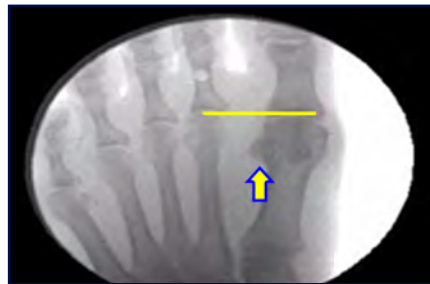NOTE: If the patient has only a mild to mild/moderate bunion deformity, this may be all that is required. If the patient has a flexible deformity, the ligaments and tendon may be able to realign the 1st metatarsal bone. To prove the point, have the patient stand in relaxed stance position and have them look at their bunion, then place their hindfoot in neutral position and again take a look at their bunion deformity – it will usually lessen in severity.

>> Hallux Limitus/Rigidus - Limited Big Toe Joint Motion

The reason why your big toe joint is stiff and has limited motion is the result of a chain reaction that starts in the back of your foot. When the ankle bone slips off the heel bone, it forces the bones of the foot forward until the first metatarsal bone, the long bone that starts in the middle of your foot and goes to the start of the big toe, is pushed into the base of the big toe joint bone. There are 6 tendons and several ligaments that pull the toe back unto the 1st metatarsal head. These tendons and ligaments have failed due to the repeated excessive stress.



Talotarsal Joint In Neutral Position



Talotarsal Joint In Relaxed Stance



TO PROVE THE POINT: have the patient stand in relaxed stance position and try to dorsiflex their toe, then place the patient's hindfoot into neutral position and again dorsiflex their hallux – there will be more motion in neutral position.

I can go in and try to clean-up or replace your big toe joint; however, the reason why you developed this problem in the first place will still exist. Until I realign your hindfoot, the problem will reoccur. The best way to stabilize your hindfoot is to place a small titanium stent into the naturally occurring space in between your ankle and heel bones. This instantly stabilizes the ankle bone and decreases the excessive hindfoot motion, reducing the forces acting on your big toe joint.

>> Posterior Tibial Tendinitis

You have a tendon that has undergone excessive strain which has resulted in the tendon becoming diseased. The reason or cause of the excessive strain starts in your hindfoot with the alignment of your ankle bone on the heel bone. Your ankle bone is partially dislocating on the heel bone which leads to the collapse of the small opening between these two bones. The forces that should be passing through the back of your heel are now acting on the inner arch. The posterior tibial tendon, along with the inner band of the plantar fascia, helps to support the inner arch. Usually the inner band of the ligament stretches out and weakens which leads to increased strain on the posterior tibial tendon. This increased strain leads to a constriction of the tendon which decreases the blood flow to the tendon while you are standing, walking or running. Eventually, this leads to a diseased tendon.

The treatment begins by stabilizing your hindfoot. We can try an arch support, but this does little to support and/or realign your ankle bone.

I recommend the placement of a small titanium stent into the space between your ankle and heel bone. This will instantly reduce the strain on the tendon. The amount of damage that has already occurred will determine if I need to go in and repair the tendon.

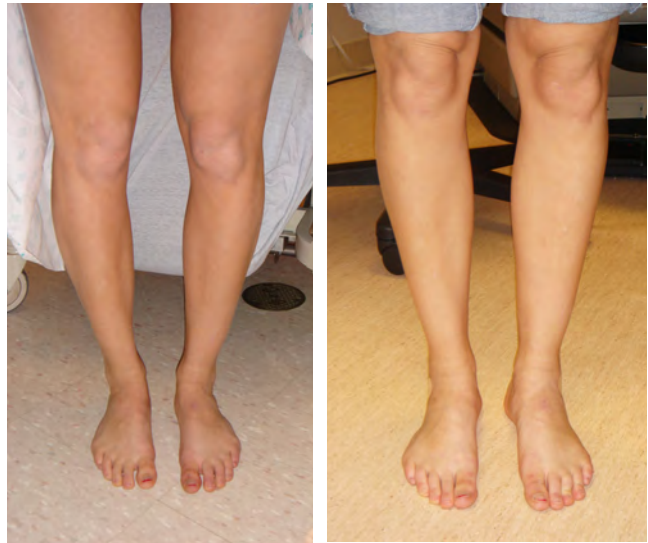

NOTE: You will also need to evaluate if the patient needs an anastomosis/ augmentation procedure or other mid-foot procedures in combination with the EOTTS procedure.

>> Knee Pain

The pain in your inner knee could actually be due to the excessive hindfoot motion. As your ankle bone slides off the heel bone, it causes your tibia to rotate outward to compensate. Over time, this may lead to a need for knee surgery.

I recommend we address this by placing a titanium stent in between your ankle and heel bone, in a naturally occurring space called the sinus tarsi. This will stop the forward and downward extra motion of your ankle bone, which in turn will lessen the compensatory actions of the bones of your leg.



TO PROVE THE POINT: have your patient stand in relaxed stance position, then place their foot into neutral position – they will usually have decreased strain to the inner knee.

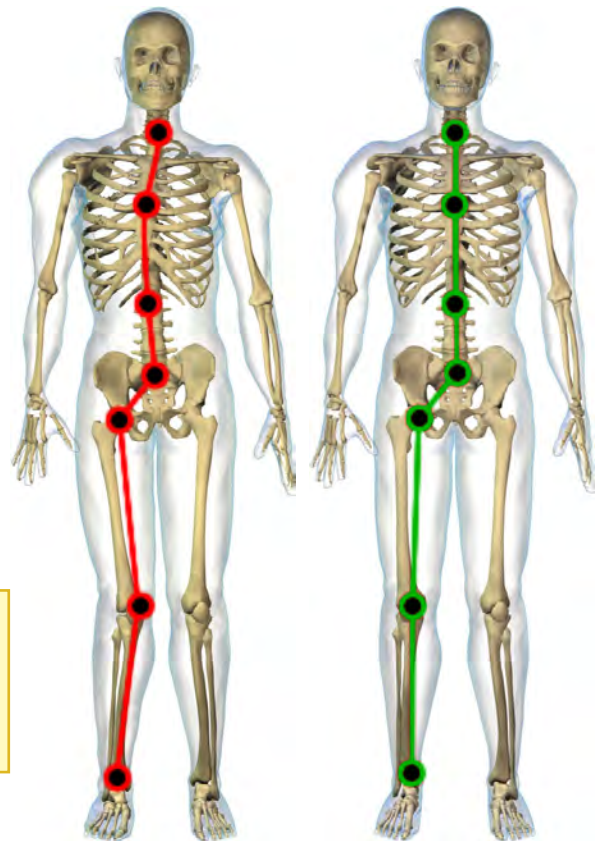
>> Hip/Back Pain

Your back pain may actually have its source in the back of your foot. What is happening is that the foundation of your body's muscle and skeletal chain is not functioning properly; the ankle is partially dislocating off the heel bone. Since the foundation isn't firm, each bone from the foot up the body is trying to compensate, causing strain.

I recommend we address this by placing a titanium stent in between your ankle and heel bone, in a naturally occurring space called the sinus tarsi. This will stop the forward and downward extra motion of your ankle bone, realigning your foundation – thereby reducing the pain in your hips and back.



TO PROVE THE POINT: have the patient stand in relaxed stance position, then have them stand in neutral position – they will report decreased strain to their hips and back.



This page intentionally left blank.

EOTTS – *HyProCure*® Preferred Surgical Technique

The challenge is that no two feet are alike and every sinus tarsi has unique characteristics. No two stent placements will be exactly alike. Sometimes the device placement will not be ideal, yet the stent will still stabilize the talus. There are guidelines that help determine “acceptable” versus “less than ideal” positioning. Positioning can also vary at different phases of the treatment and recovery, for example, intra-op versus three weeks post-op. **Getting the initial placement as close to ideal as possible is of extreme importance.**

Once the surgeon has identified that the patient is a candidate for the EOTTS procedure and the patient has chosen to undergo the EOTTS procedure with *HyProCure*®, it is important to make sure the surgical technique is performed correctly.

As a stand-alone procedure, EOTTS - *HyProCure*® can be performed under twilight sedation with local anesthesia.

Pre-Op Antibiosis

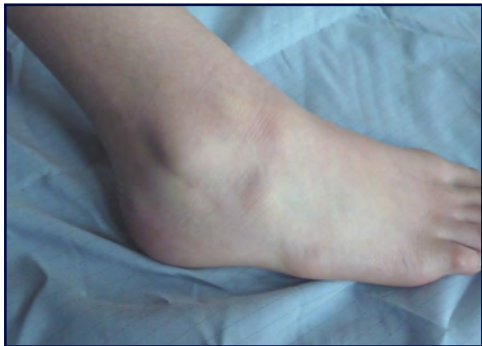The general rule is that the implantation of a foreign body warrants the use of a pre-procedure antibiotic within 1 hour prior to the procedure. While there have been no scientific published studies showing the effectiveness of this protocol with the use of a sinus tarsi implant, it is recommended to prescribe the antibiotic as a precautionary measure, rather than face the possibility of a post-procedure infection.

Hemostasis

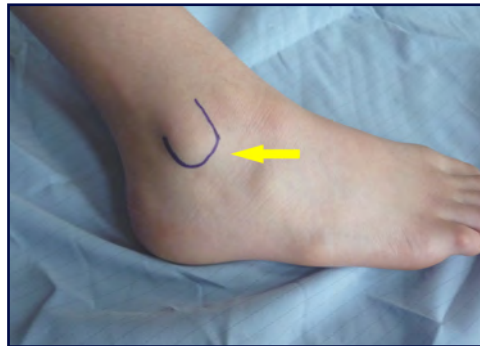An ankle tourniquet is not necessary. There will be very little bleeding and the tourniquet will limit range of motion testing. If *HyProCure*® will be performed in conjunction with other procedures, an ankle tourniquet can be used, but it should be left deflated for the *HyProCure*® EOTTS procedure.

Landmarks

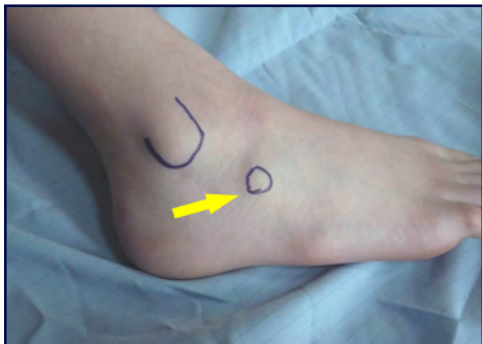It is important, as with any surgical procedure, to consider the pertinent anatomical structures that may be encountered. Incision placement is also very important.



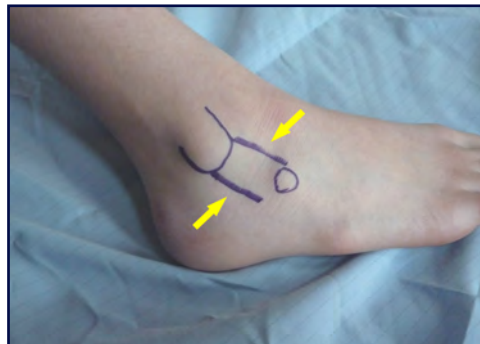Dorsal-Lateral Aspect of the Foot/Ankle



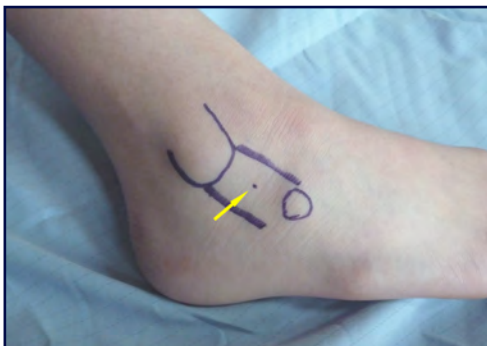Fibular Malleolus



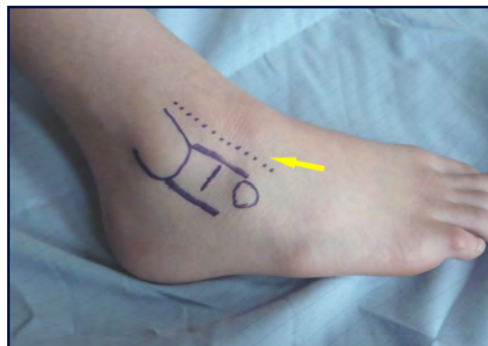Anterior Calcaneal Tubercle



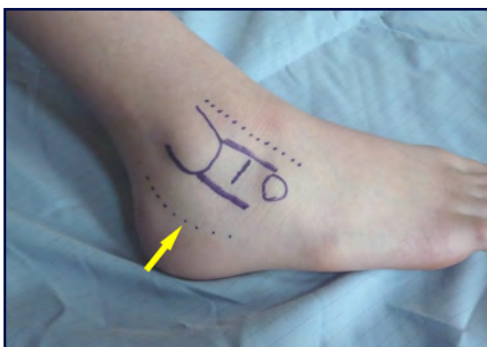Anterior & Posterior Margins of the Sinus Tarsi



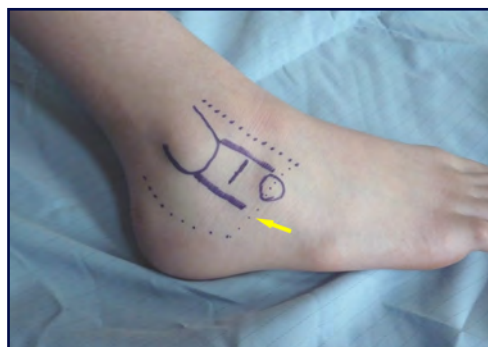Center Point of the Sinus Tarsi



Intermediate Dorsal Cutaneous Nerve



Sural Nerve



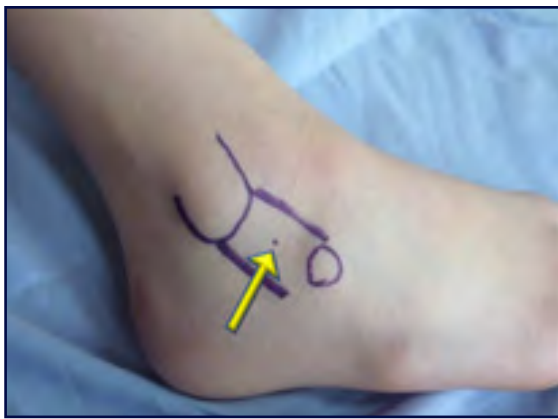Communicating Branch/Nerve

Pre-Op Sinus Tarsi Injection

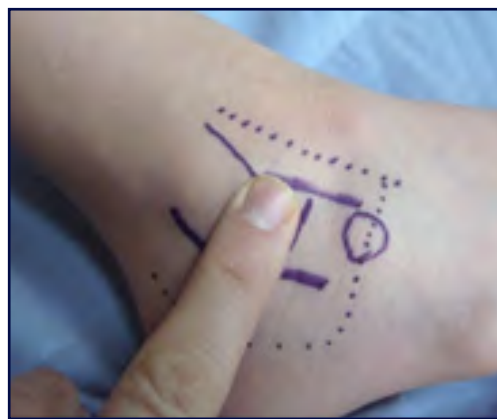The EOTTS-**HyProCure**® procedure requires the introduction of long-lasting anesthetic to the skin and to the sinus and canalis portions of sinus tarsi.

It is strongly recommended to inject up to 10 ccs of local anesthetic solution to this area prior to performing the EOTTS procedure as this leads to a dramatic decrease in post-op pain and speeds recovery.

It is also **strongly recommended** to combine a steroid (0.5–0.75 cc) to quell the inflammatory reaction within the soft tissues.



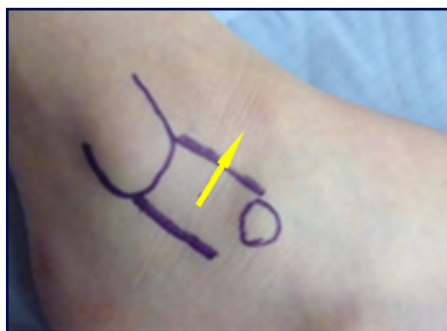Insert needle into the Center Point of the Sinus Tarsi



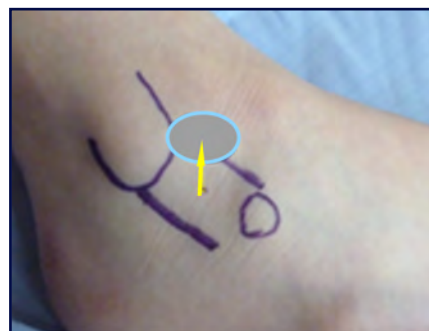1 Index Finger Distal to the Fibular Malleolus

Insert 1 CC of injectable superficially just under the dermal layer.

Redirect the needle anteriorly under the dermis. It's important that the medication reaches the anterior border of the incision site. It is also recommended to insert 1-2 ccs in the area of the talofibular ligament. Then redirect and inject into the posterior-plantar border of the incision site.



Advance and Inject to the Anterior Margin of the Sinus Tarsi

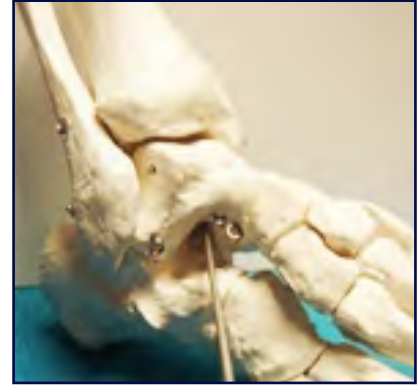
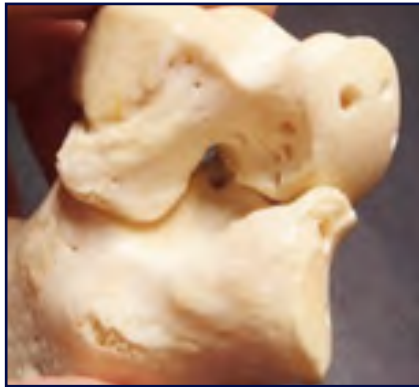
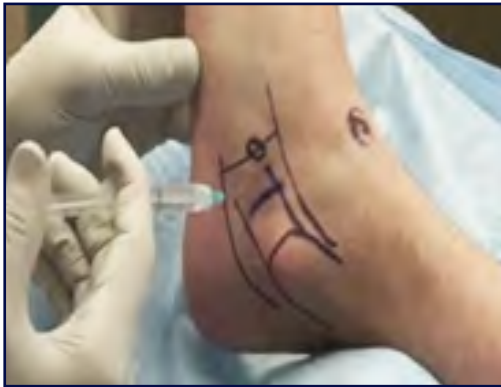Anterior TaloFibular Ligament



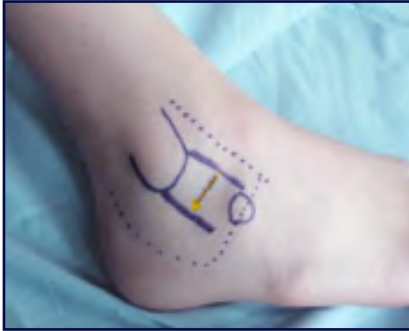Redirect, Advance and Inject to the Posterior Margin of the Sinus Tarsi

Finally, redirect the needle and aim toward the posterior aspect of the medial malleolus and insert the rest of the local anesthesia deep into the sinus tarsi, approximately 5-7 ccs – remember the oblique orientation of the sinus tarsi chamber: **anterior-distal-lateral to posterior-proximal-medial**.

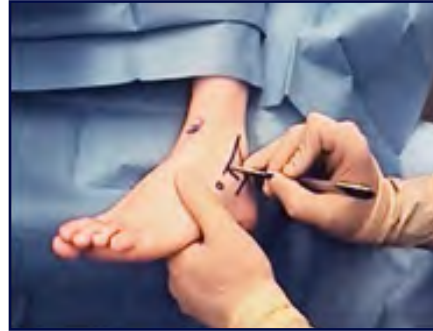

>> STEP 1: Skin Incision

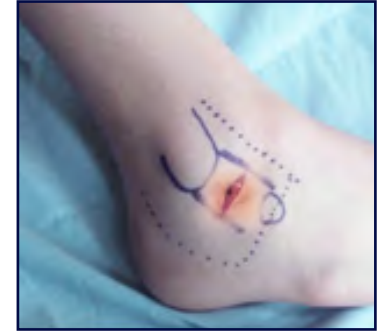The skin incision should be approximately 1.5–2.0cm in length, utilizing a #15 blade-scalpel. It should start at the anterior/distal border and extend posteriorly/plantarly following the relaxed skin tension lines. **Only** incise the skin/dermis.



Mark the ankle in preparation for making the incision.



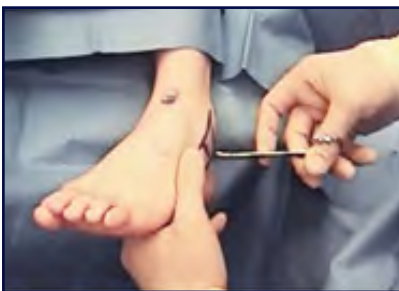Start the incision on anterior border and extend it posteriorly.



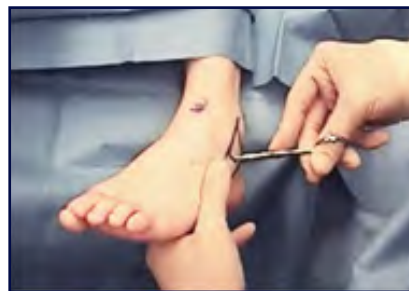The incision should not extend beyond the anterior-posterior boundaries of the sinus tarsi.

>> STEP 2: Blunt Dissection

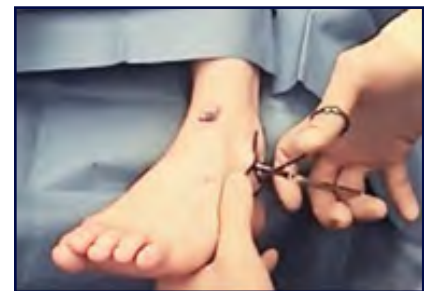Insert the curved Steven's tenotomy scissors (it is preferred to use GraMedica's **HyProCure®** Sinus Tarsi Decompression Scissors), with the tips closed, into and through the deep fascia, through the dermis. Open the tips of the scissors once the tips have pierced the superficial tissues (approximately 3-5 mms). This technique lessens the chance of transecting an aberrant nerve branch.



Insert scissors with tips closed. Make sure the tips of the scissors are angled posteriorly.



Puncture the tips of the scissors through superficial tissue.

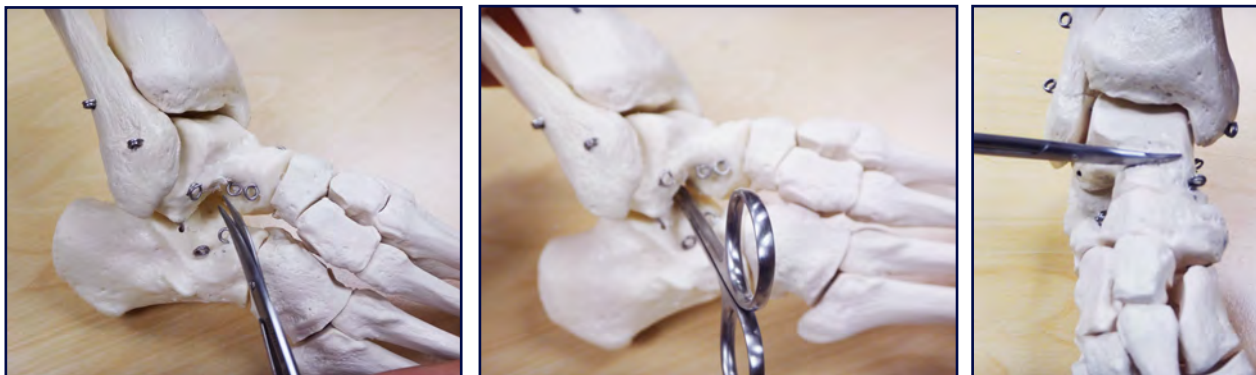

Spread open the finger holes of the scissors. This separates the tissues to create an opening into the sinus tarsi.

>> *STEP 3: Sinus Tarsi Decompression*



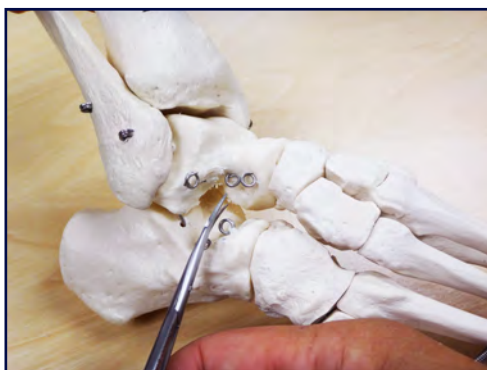The soft tissue contents within the sinus tarsi must be decompressed using curved Stevens tenotomy scissors. The tip of the scissors **MUST** be angled **posteriorly**. If the curve/tip is angled anteriorly, the structures within the canalis tarsi will not be transected and **this could result in failure of the procedure**.



The tips of the scissors must be angled **posteriorly**, aiming towards the **posterior end of the medial malleolus**. The artery, nerve and vein to the sinus tarsi are directly under the talus, however, the blunt upper end of the scissor will prevent transection of these tissues.



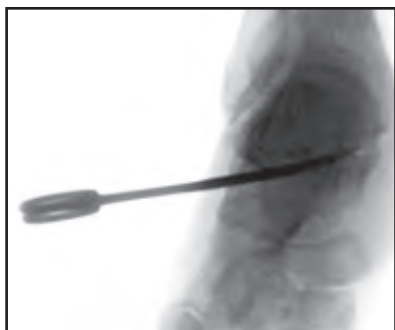Transecting the entire talocalcaneal ligament in the canalis portion of the sinus tarsi is a crucial part of the technique. Failure to adequately decompress the entire sinus tarsi could result in mal-position of the **HyProCure®** stent.



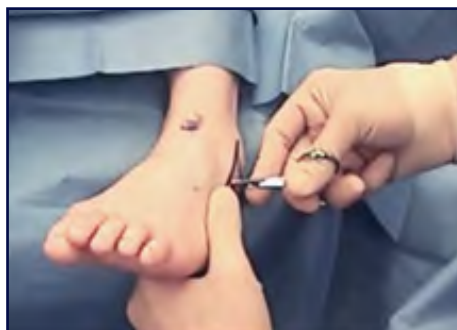This is the incorrect way to decompress the sinus tarsi.

Notice the tips of the scissors are pointing **anteriorly**, rather than **posteriorly**. The structures within the canalis are left intact and therefore will prevent the deep insertion of the threaded portion of **HyProCure®** into the canalis tarsi.

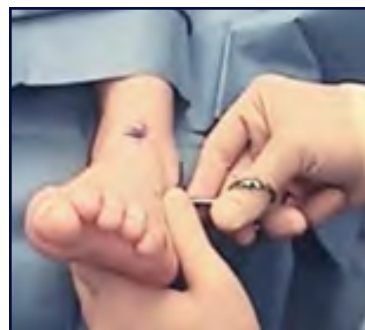This is the correct way to decompress the sinus tarsi.



Correct placement of scissors under fluoroscopy.



Advance the scissors into the sinus tarsi and cut the mid-substance of soft tissue contents.



Make sure the sinus tarsi is in an open position.

>> **STEP 4: Trial Sizing –**
Determining the Size of the HyProCure® Device

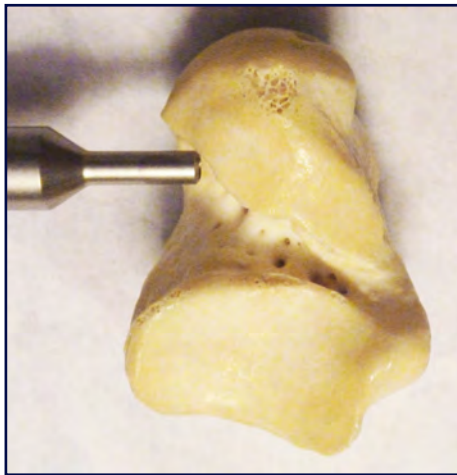
The goal is to determine which size stent will provide talotarsal stability while at the same time allowing normal talotarsal pronation/ supination. Start with the size 6 (most common size), and work up or down from there based on the results. The goal is to achieve about **3–4 degrees of pronation**.



HyProCure sizers in surgical tray.



NOTE: If two sizes appear to give similar results, the smaller size it is usually the preferred choice. It is better to under-correct rather than over-correct.



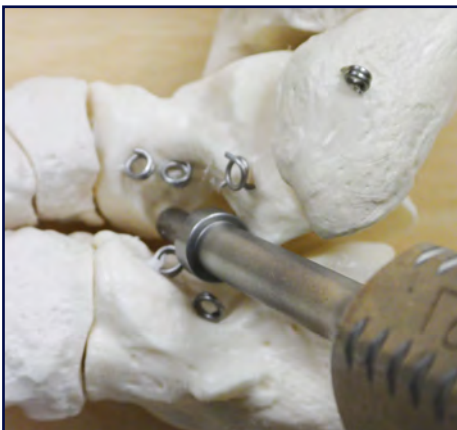The image shows the tip of the sizer is hitting against the lateral neck rather than entering into the canalis tarsi.

It's important to insert the sizer correctly. Make sure to insert the sizer so that the tip does NOT hit the lateral neck of the talus (as it's doing in the photo at left) The sizer needs to completely enter the canalis tarsi.

Remember to aim the tip of the sizer to the posteromedial aspect of the medial malleolus.



HyProCure Sizers.



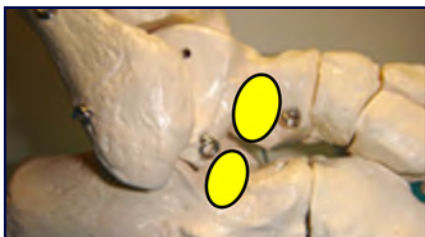This is the incorrect way to trial size.

Notice that the tip of the sizer is hitting against the lateral neck of the talus and not entering into the canalis tarsi. This will result in over-sizing and will likely cause failure of the procedure.



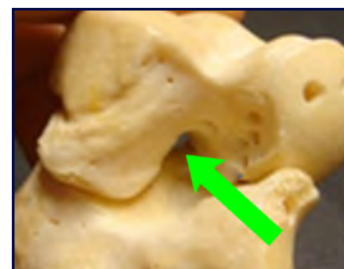
NOTE: It's also important to make sure that the tip of the sizer does NOT hit against the floor of the sinus tarsi lateral to the entrance of the canalis tarsi. The sizer needs to enter the central part of the canalis tarsi.

>> *STEP 4: Trial Sizing (continued)*



Make sure the tip of the sizer is not hitting against the lateral neck of the talus or against the floor of the sinus tarsi/ calcaneus.

Insert the trial sizer tip into the entrance of the canalis tarsi here.



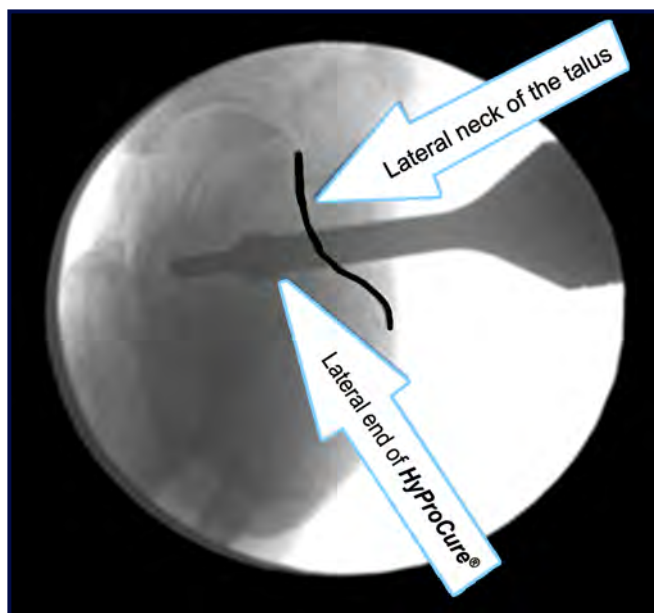
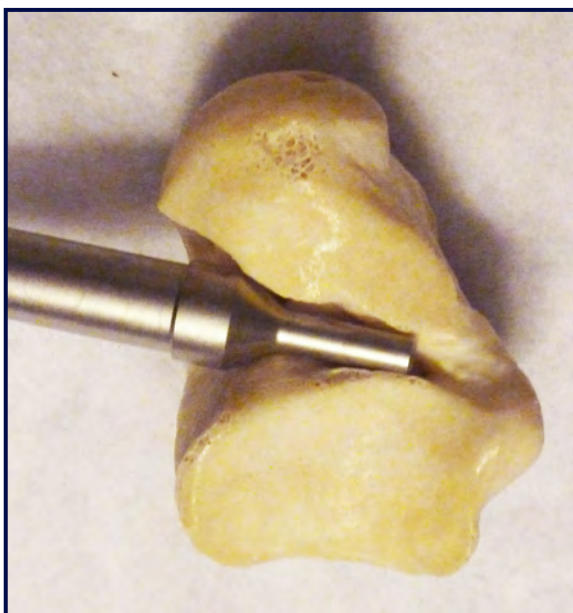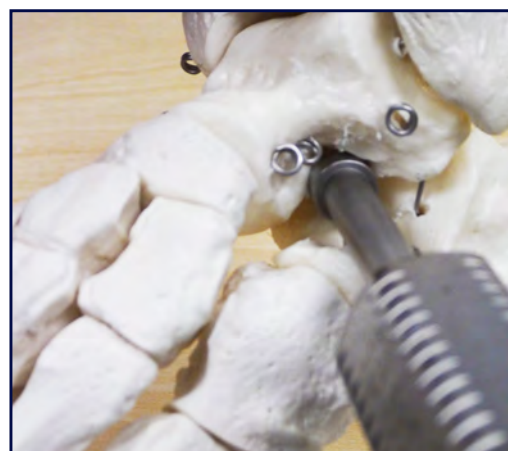Insert the trial sizer tip into the entrance of the canalis tarsi.



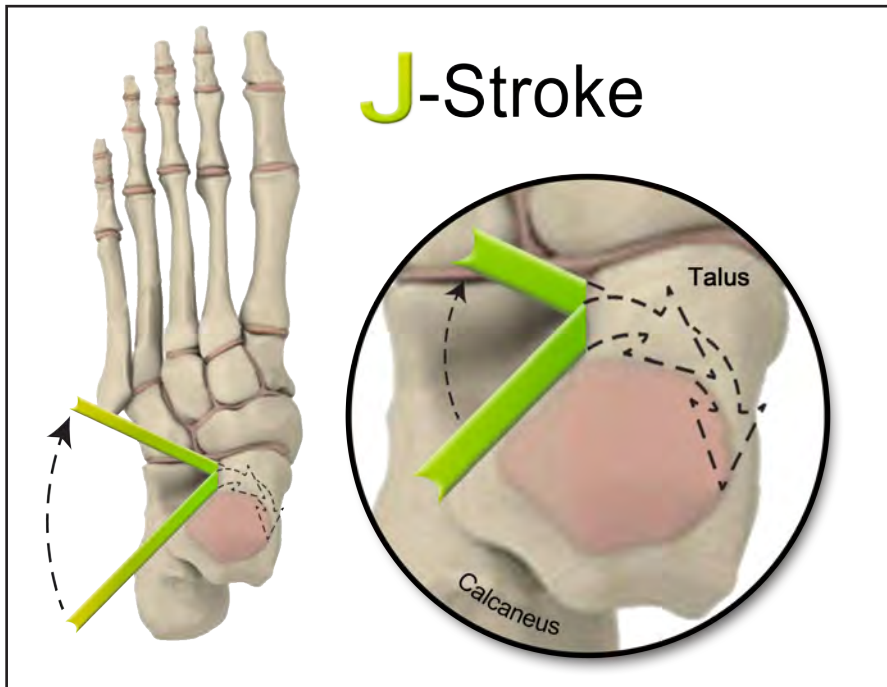
NOTE: It is important that you check the position of the sizer by taking a DP view of the talotarsal joint with fluoroscopic imaging. The lateral view is not helpful.

CORRECT SIZER PLACEMENT

The images below show the correct placement of the sizer within the sinus and canalis portions of the sinus tarsi.



>> STEP 4: Trial Sizing (continued)

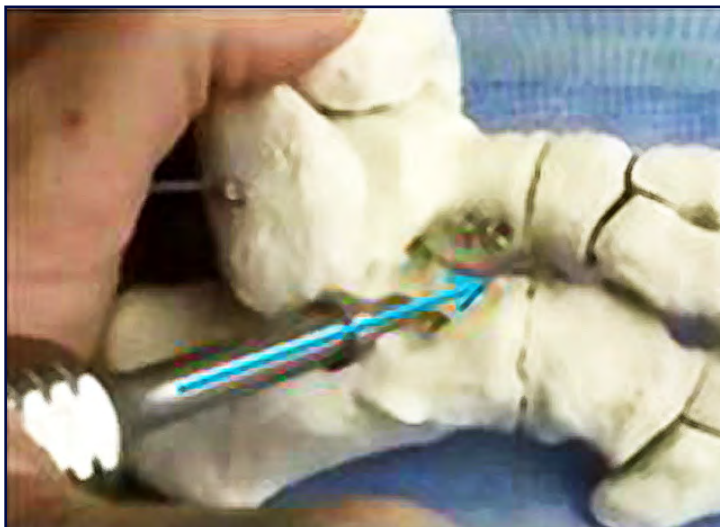

HINT:

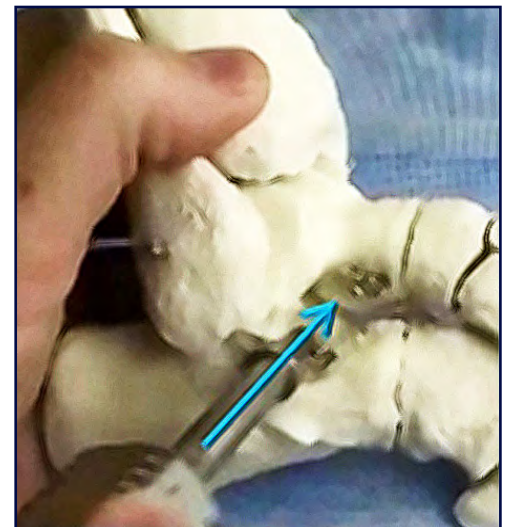
Use the “J-Stroke” to make sure that the sizer is entering the canal.

The “J-Stroke” is a “J” shaped motion that follows the lateral process around the talus, helping to ensure the sizer is completely inserted in the canal.

SIZING STEP 1 – Insert the tip of the sizer with the tip aimed slightly anterior/distally.



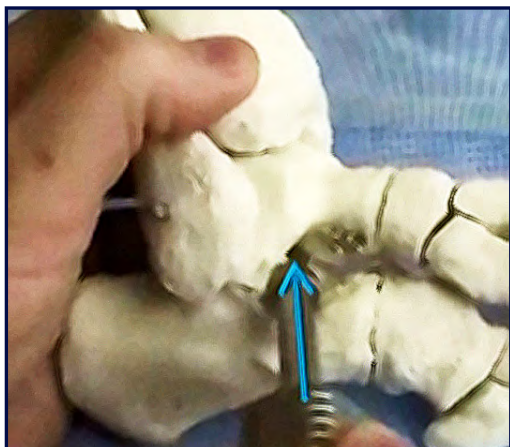
Tip is inserted into the incision, angles distally.



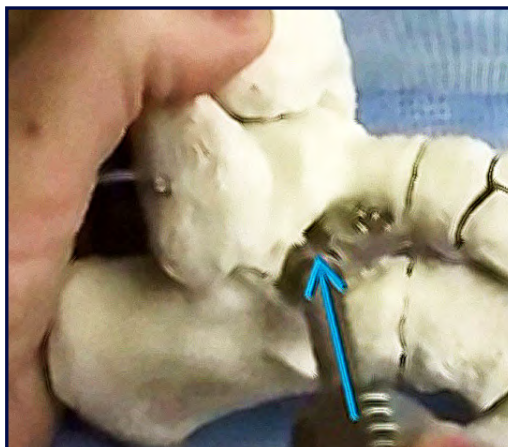
Tip is angled medially.

>> *STEP 4: Trial Sizing (continued)*

SIZING STEP 2 – Turn and curve the tip posteriorly following the lateral process. Keep the handle horizontal, making sure the sizer is horizontal and not angled dorsally.

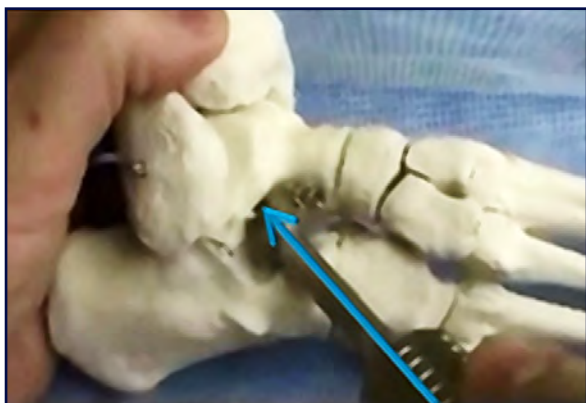

Tip is redirected posterior-medially.

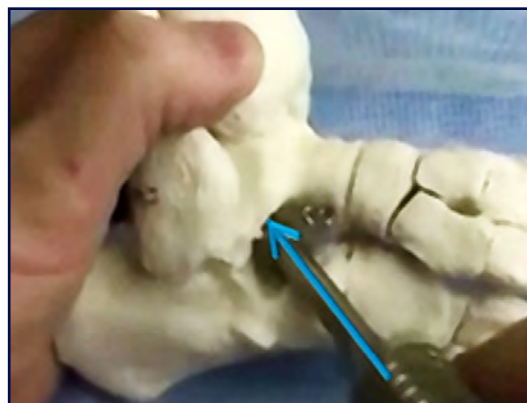

Tip is directed more posterior and the handle is more distal.

SIZING STEP 3 – At this point the tip should be in line with the sinus portion. Advance the tip into the canalis tarsi until the tapered portion of the sizer abuts the entrance to the canalis tarsi.



Tip is now in line with the oblique orientation of the sinus tarsi.

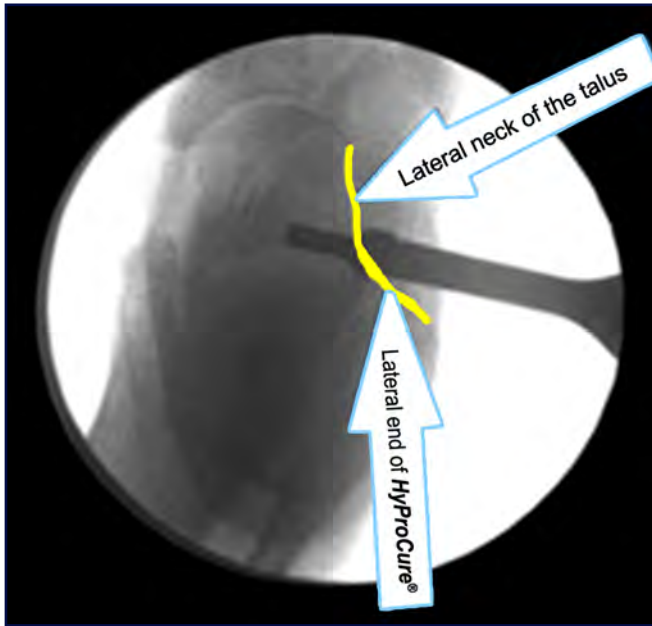


Push the sizer in as deep as you can; use a twisting motion if necessary.

>> STEP 4: Trial Sizing (continued)

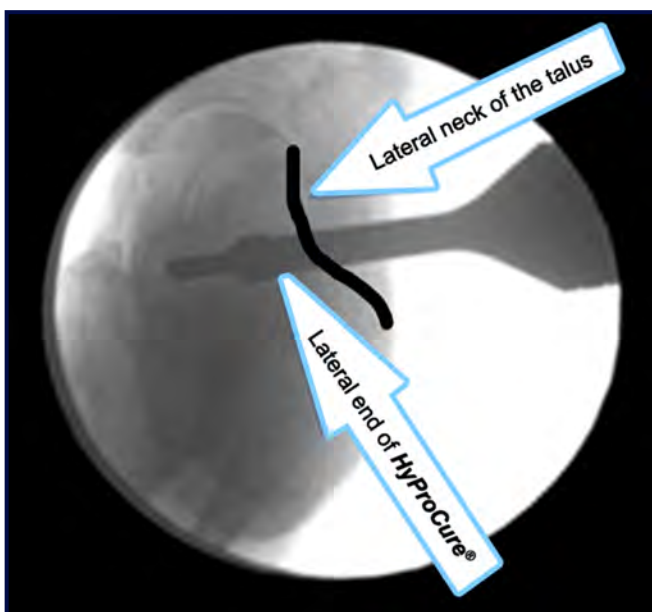
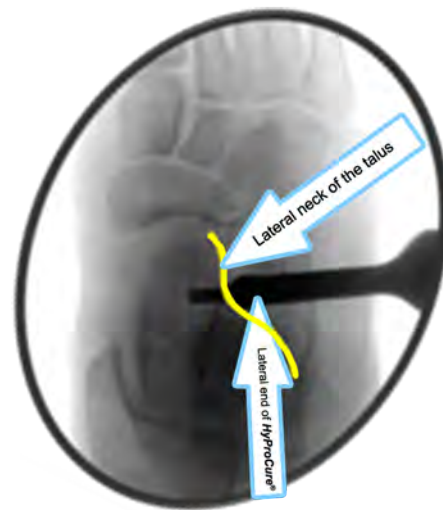
The images below show that the tip of the sizer is pushing against lateral neck of the talus. Notice the lateral end of **HyProCure®** is **NOT** deeper than the lateral neck of the talus.

Failure to properly insert the sizer will result in too large of a stent being chosen. Also, notice the horizontal alignment of the sizer with relation to the orientation of the sinus tarsi. The sizer has been inserted lateral-to-medial instead of **anterior-distal-lateral to posterior-proximal-medial**.



INCORRECT Trial Sizer Placement:

It is strongly recommended that that you check trial sizer position under fluoroscopy.



CORRECT Trial Sizer Placement:

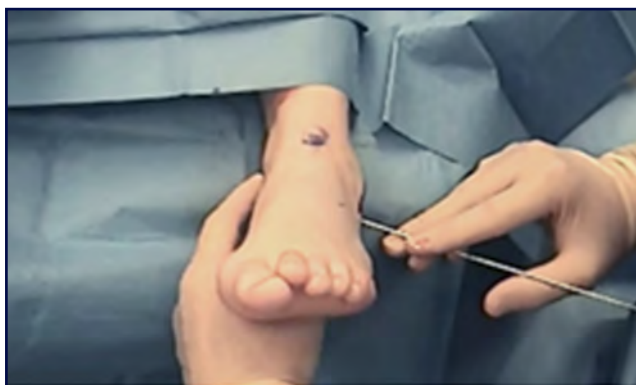the lateral end of the sizer should be deeper than the lateral neck of the talus.

>> *STEP 4: Trial Sizing (continued)*

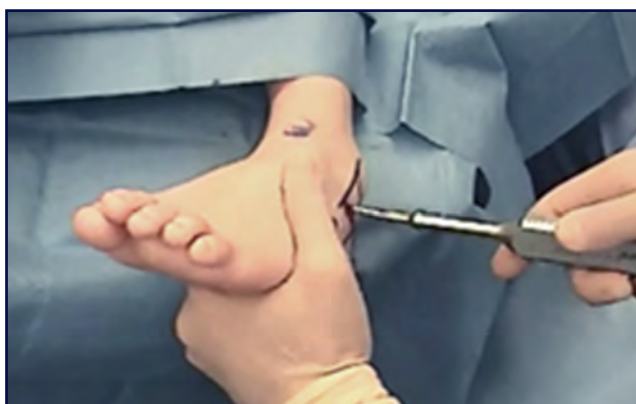You may elect to use the guide wire to help correctly place the sizer and the stent. If you have difficulty placing the guide into the canalis tarsi, this could indicate:

- 1) inadequate cutting of the soft tissues or
- 2) improper placement (guide wire not entering into the canalis tarsi, but passing anterior and inferior below the neck of the talus.)

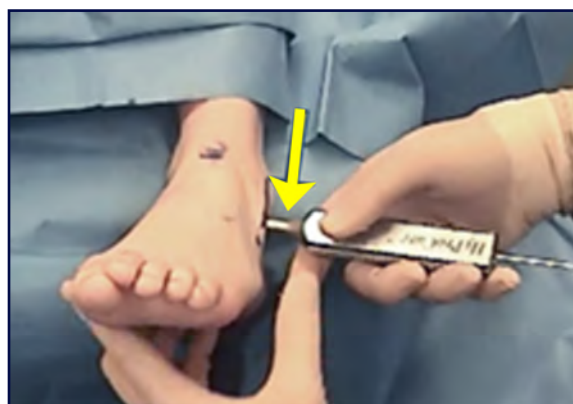Remember the oblique orientation of the sinus tarsi.



Make sure to insert the guide wire into the canalis tarsi. Head to the posterior aspect of the medial malleolus.

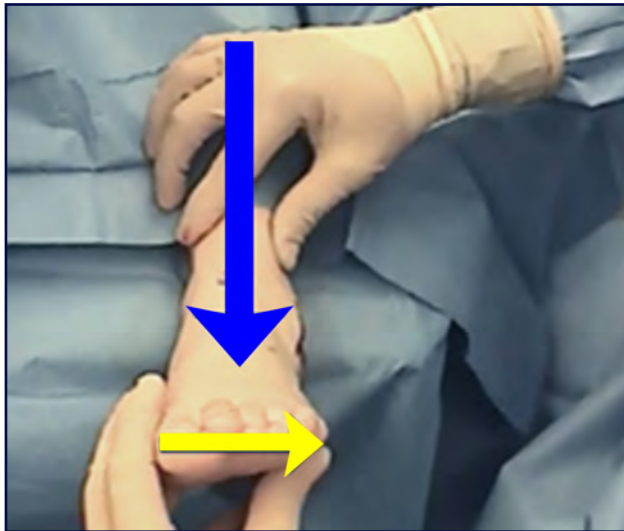


Supinate the foot to maximally open the sinus tarsi.

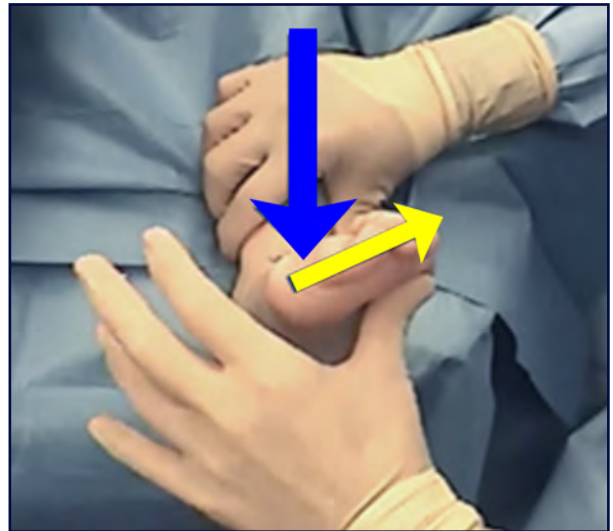


Use a twisting action and aim to the posterior aspect of the medial malleolus. Notice only an index finger width of the sizer stem remains visible.

>> STEP 4: Trial Sizing (continued)



TaloTarsal Neutral Position



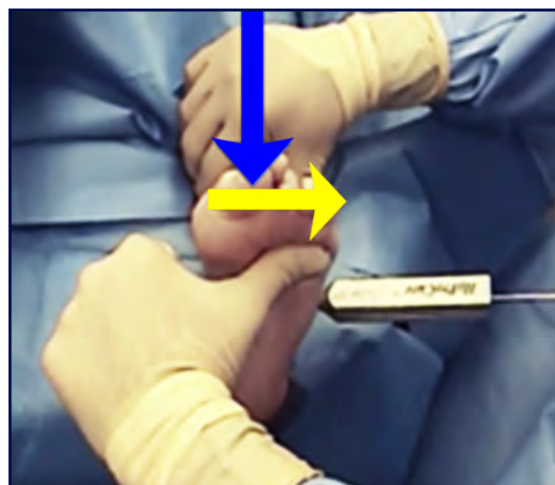
TTJ Pronation > 5 degrees



Maximally load the 4th and 5th metatarsal head/neck area.



Goal is "some" pronation: 3-4 degrees.

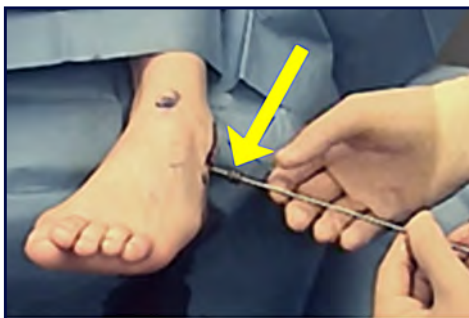

TTJ shows no pronation – insert the next smaller size *HyProCure*® stent.

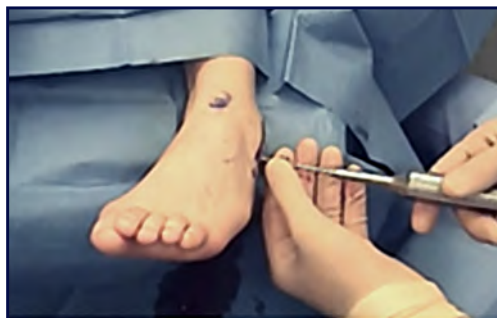>> **STEP 5: HyProCure® Stent Placement**

Place the **HyProCure®** stent onto the guide wire, then insert the driver onto the guide wire. Engage the tip of the driver into the lateral end of the **HyProCure®** device. Advance the tip of the stent as deep as possible into the sinus tarsi. Twist/rotate the handle of the driver to insure placement is as deep as possible within the sinus tarsi.

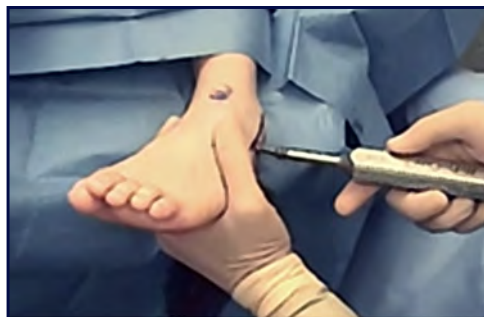It should **not** be possible to over-insert this device, unless a smaller than appropriate device is used or unless the patient has a congenital sinus tarsi chamber wall deformity.



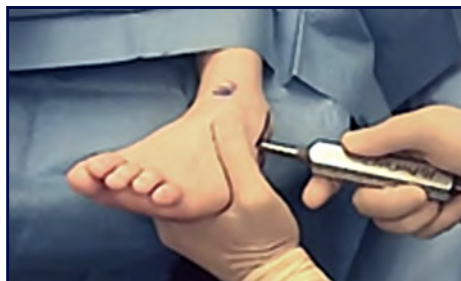Place the desired **HyProCure®** stent on the guide wire.



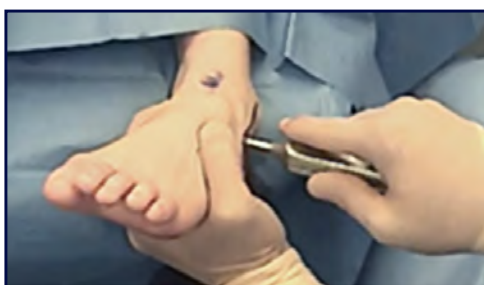Place the **HyProCure®** driver on the guide wire.



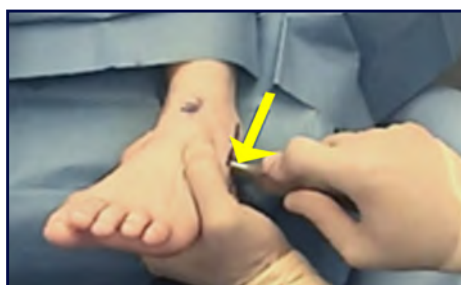Engage the **HyProCure®** driver into the lateral end. Supinate the talotarsal joint.



Remove the guide wire once the lateral end of **HyProCure®** is no longer visible.



Advance **HyProCure®** deep into the canalis tarsi. Aim to the posterior aspect of the medial malleolus.



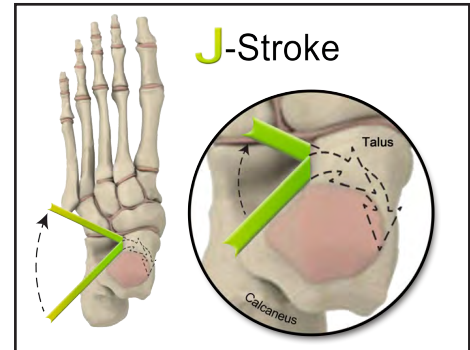
Typically, there is only one index finger width of shaft visible.

>> STEP 5: *HyProCure*® Stent Placement (continued)

Use the same “J” stroke described in the Trial Sizing Section to ensure the tip of the stent enters into the canalis tarsi.

Even though there are threads on the end of *HyProCure*®, it is not a screw. The threads should not engage into bone, but into the soft tissues. Those tissues will grow around and adhere to *HyProCure*®, fixing it within the sinus tarsi.

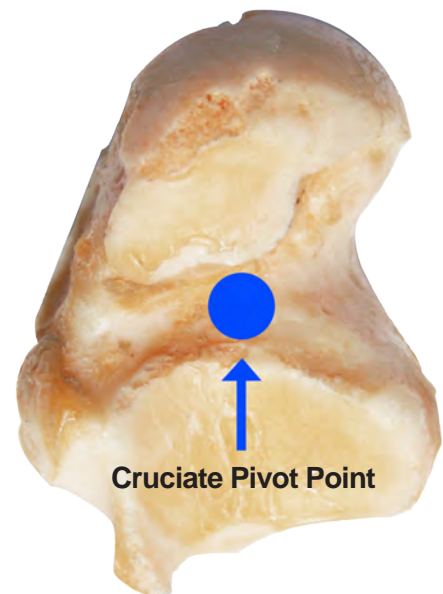
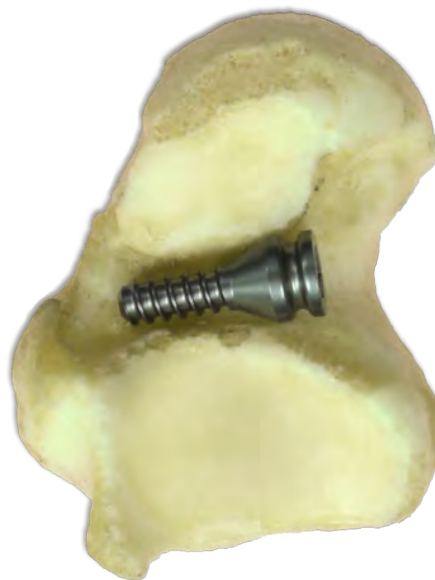Once *HyProCure*® is fully inserted, rotate it clockwise a couple of turns with the driver. This co-aligns the ligament fibers on the threads of the stent.



The ideal location to stabilize the talotarsal mechanism is at the cruciate pivot point. This is where the tapered portion of *HyProCure*® functions to stabilize yet allow normal talotarsal joint pronation/supination.

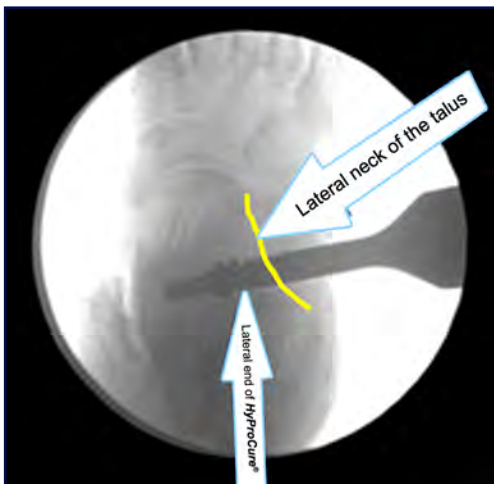


NOTE: Check final position via DP fluoroscopic examination.



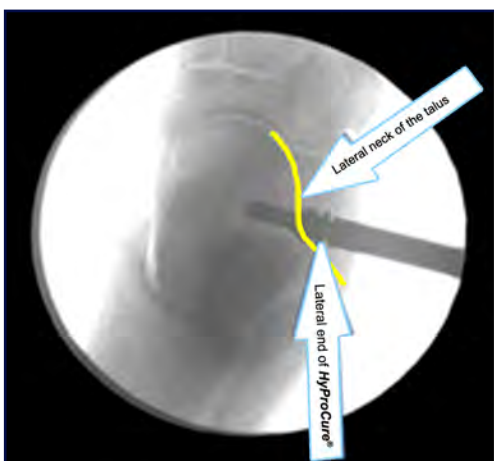
>> STEP 5: *HyProCure®* Stent Placement (continued)

The lateral end of the stent should be deeper than the lateral neck of the talus. It is better to use a slightly smaller device and have it inserted deeper than to have a superficially placed device that has a higher risk of displacing post-procedure.



THIS IS AN IDEAL PLACEMENT.

HyProCure® is aligned along with the sinus tarsi. The lateral end of *HyProCure®* is deeper than the lateral neck of the talus.



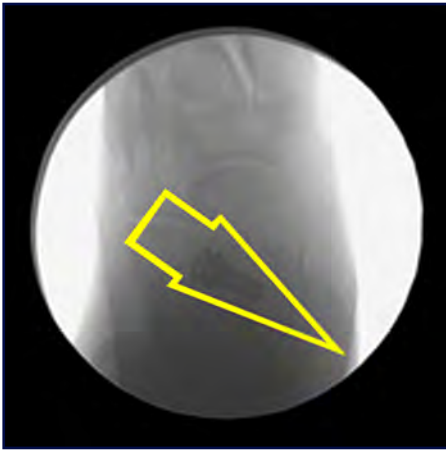THIS IS AN INCORRECT PLACEMENT.

HyProCure® is being placed in a lateral to medial fashion instead of obliquely along the natural orientation of the sinus tarsi. The tip of *HyProCure®* is abutting the lateral neck instead of entering into the canal.

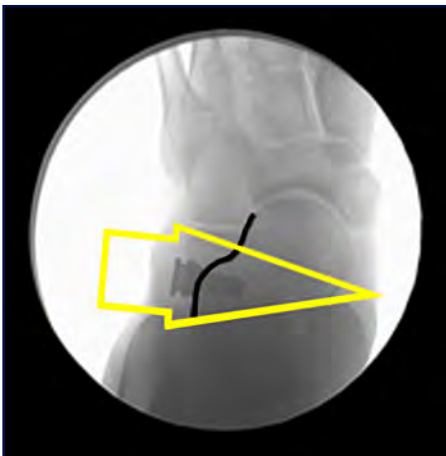

REMEMBER that the orientation of every sinus tarsi is different. No two are alike. Some will appear to be oriented more lateral to medial whereas others are very oblique (anterior-lateral-distal to posterior-medial-proximal).

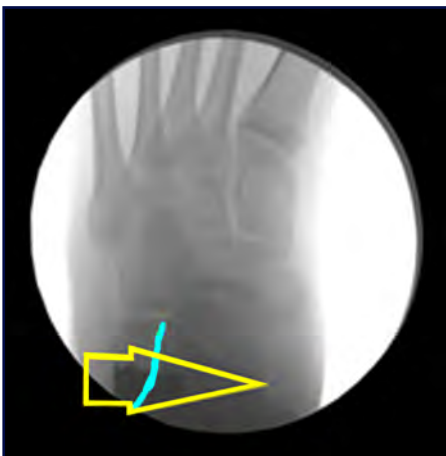There is an “anatomic ideal” placement that we are trying to achieve as well as a “functional-ideal” placement – this is when the device “seeks its own level.” In the first few weeks post-operatively, the device may *slightly* reposition to seat itself where it will function best. Ultimately, as long as the talotarsal joint dislocation is stabilized and there is improvement of the radiographic angles, then the surgical correction has been successful.

>> STEP 5: **HyProCure®** Stent Placement (continued)**IDEAL INTRA-OP PLACEMENT**

NOTICE the angle of insertion, oriented correctly; the lateral end of the device is deeper than the lateral neck of the talus.

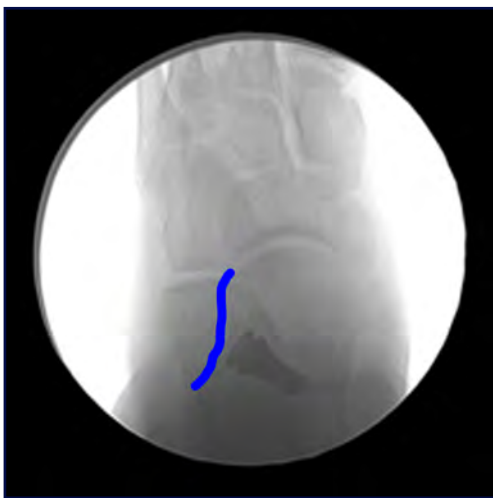

This is a **LESS THAN IDEALLY** positioned device. Placed lateral to medial, the end of the device is not deep enough.

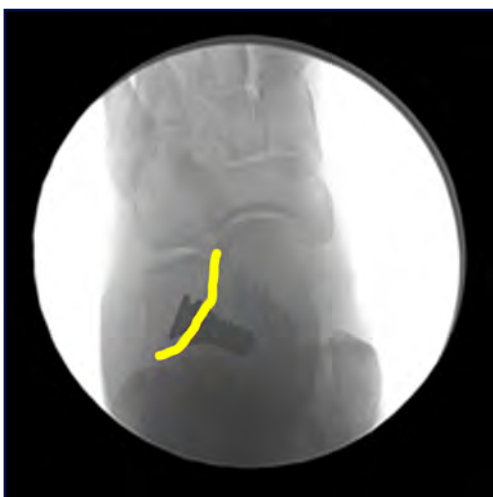**A LESS THAN IDEALLY PLACED DEVICE.**

IF THIS POSITION IS SEEN INTRA-OP: Remove the device, ensure proper decompression of the sinus tarsi and re-trial size.

IF THIS POSITION IS SEEN POST-OP: If correction is maintained, the patient is not experiencing pain and there is stabilization of the talotarsal joint, there is no immediate need for revision.

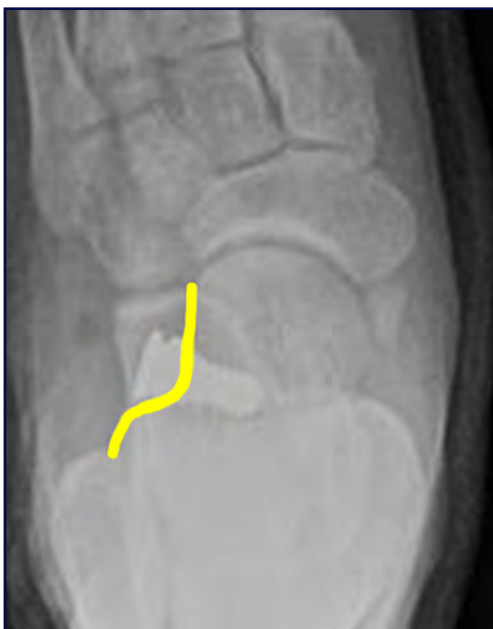>> STEP 5: *HyProCure®* Stent Placement (continued)**THIS IS AN IDEAL PLACEMENT.**

The lateral end of *HyProCure®* is deeper than the lateral neck of the talus. Notice the anterior-distal-lateral to posterior-proximal-medial orientation. This device is functioning with the talotarsal joint, not against it.

**THIS DEVICE IS NOT IDEALLY INSERTED.**

The lateral end of the device is too superficial. Make sure that the deep structures within the canalis are decompressed/cut and that the tip of the device is entering into the canalis tarsi and not abutting the lateral neck of the talus.

- If you see results like this intra-op, attempt to insert the device deeper.
- If you see results like this post-op, the placement it is still acceptable.

**PLACEMENT IS NOT IDEAL; TOO SUPERFICIAL.**

The lateral end of *HyProCure®* is not deeper than the lateral neck of the talus.

INTRA-OP: DO NOT BE SATISFIED! It is possible that this patient has a very narrow canalis. It is better to use a smaller size that can be inserted deeper, than to use too large a size that cannot be inserted deep enough.

POST-OP: If the talus is stabilized on the tarsal mechanism and there is normalization of the radiographic angles, this placement may be acceptable.

>> **STEP 5: HyProCure® Stent Placement (continued)**

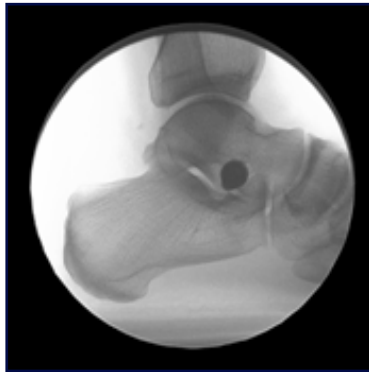


NOTE: The position of *HyProCure®* may slightly shift from the intra-operative image(s). This is simply due to the fact that the intra-operative image was taken non-weightbearing.

Upon weightbearing, *HyProCure®* will seek the ultimate position where it will best function to stabilize the talotarsal joint mechanism.

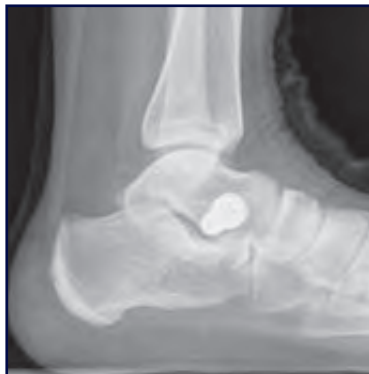- It is possible that even with ideal initial placement there could be a failure of *HyProCure®* to maintain its position within the sinus tarsi and incur lateral displacement.
- It is also possible that, due to anatomical variability, EOTTS with *HyProCure®* just cannot work and another form of treatment will be necessary.

Less Than Ideal Post-Op Placements

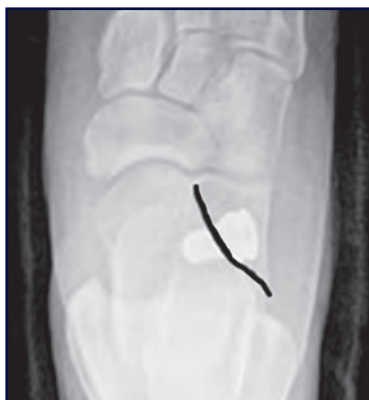

THIS LATERAL X-RAY SHOWS A PURELY LATERAL TO MEDIAL PLACEMENT.

If you use your imagination, you can see down the central cannula. Most likely the tip of the device is abutting the lateral neck of the talus and is not inserted into the canalis tarsi.



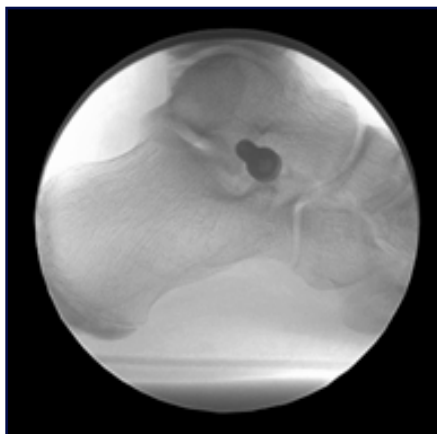
THE LATERAL VIEW SHOWS A DORSAL-PLANTAR POSITION INSTEAD OF PLANTAR-DORSAL.



The tip of the device is hitting against the floor of the sinus tarsi. The lateral end of the device is not deeper than the lateral neck of the talus. The tip of the device has not been placed into the canalis tarsi.

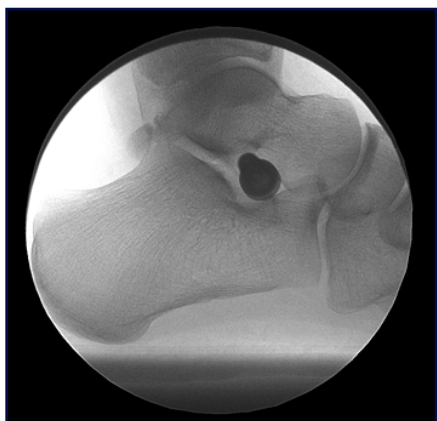>> STEP 5: *HyProCure®* Stent Placement (continued)

Ideal Post-Op Placements



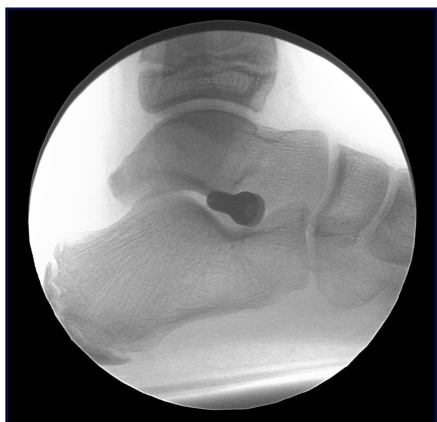LATERAL VIEW SHOWING THE DESIRED PLACEMENT of *HyProCure®*.

Notice that the threaded portion of *HyProCure®* is posterior and slightly dorsal. That is the natural orientation of the sinus tarsi.



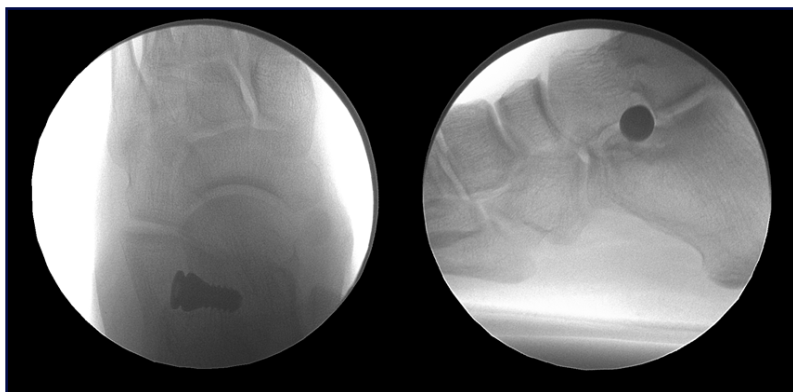
NOTICE THE POSTERIOR ALIGNMENT OF THE THREADED PORTION OF *HyProCure®*.

Every foot will be slightly different and some may be more horizontal while others may be slightly more dorsal.



IDEAL *HyProCure®* PLACEMENT - LATERAL VIEW.

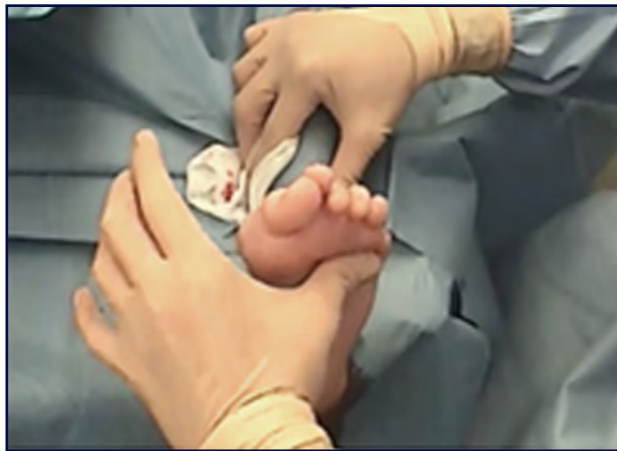The threads are aimed dorsal-posterior.



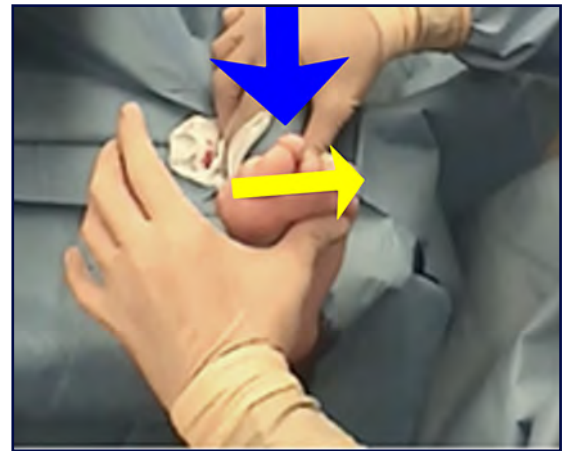
The lateral view shows a lateral to medial placement of *HyProCure®*, whereas the DP view shows a slightly posterior angulation. Still would be an acceptable placement. Ideally we would like it deeper when possible.

>> **STEP 5: HyProCure® Stent Placement (continued)**

Check talotarsal joint range-of-motion and stability prior to skin closure.



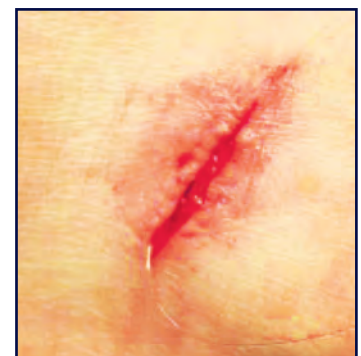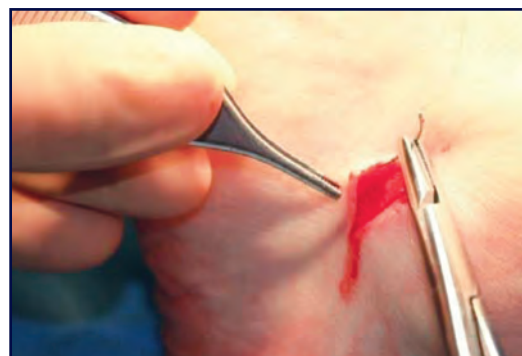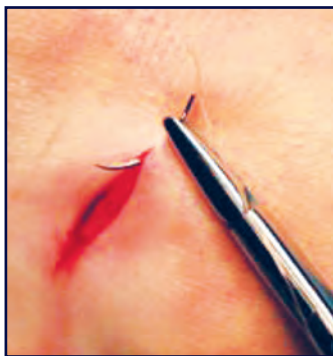Check maximum TTJ pronation & range of motion/stability with **HyProCure®** in situ.



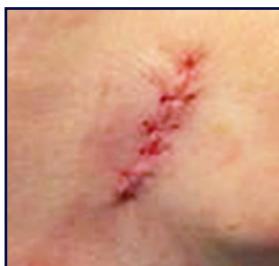3-4 degrees of TTJ pronation.

>> **STEP 6: Closure**

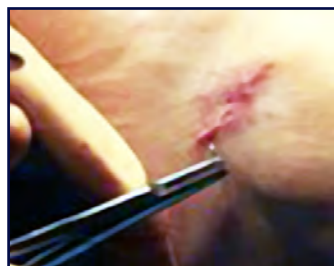Closure is per surgeon's choice. It is not necessary to close deep tissue, only the skin. Using a bioabsorbable suture is generally preferred. A running subcuticular combined with a continuous simple suture is recommended.



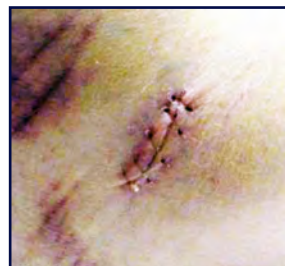Subcuticular First



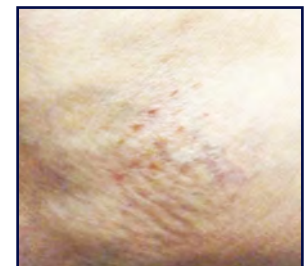Running Continuous



Finished



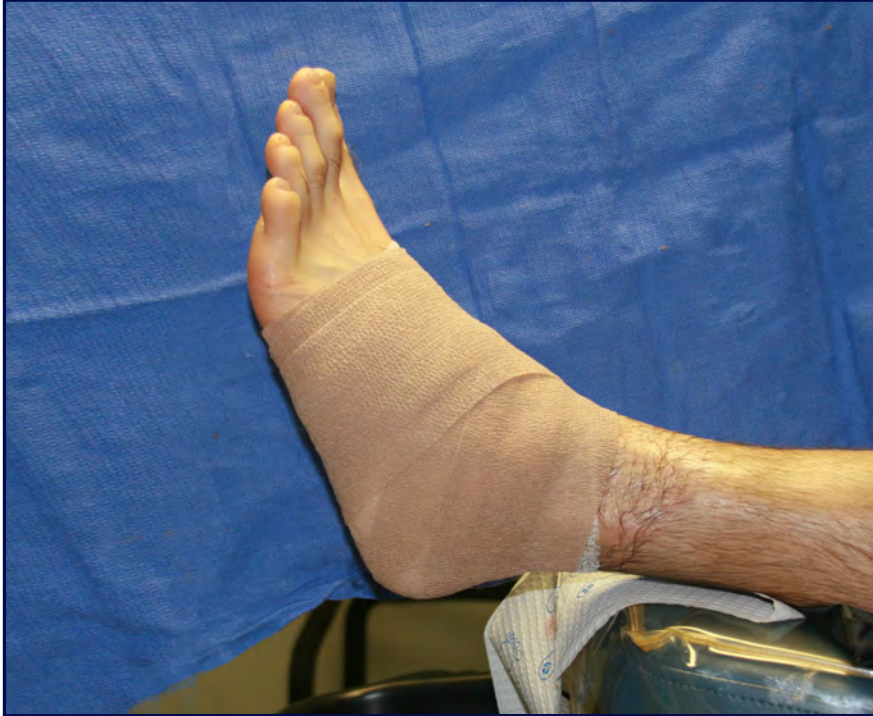2 weeks post-op



2 months post-op

>> *STEP 7: Bandaging*

Sterile 2x2 or folded 4x4 gauze pads are placed against the incision and held in place with 3 inch sterile gauze-roll, finally a compression wrap (self-adherent) is lightly applied as an outer bandage. Plaster or fiberglass casting is not necessary unless there is concern of an over-active patient.



Immediate Post-Op (Suggested) Protocol

The following recommendations apply only when performing EOTTS-*HyProCure*® as a stand-alone procedure. If additional procedures are performed, the post-op protocol should follow that of the procedure with the most restrictive course.

Early guarded weightbearing is recommended. There will be a period of adjustment while the soft tissues adapt to the new foot position. The sooner this adjustment begins, the sooner the patient will feel comfortable with their *HyProCured*® foot.

The patient should stay off their foot as much as possible in the first few days following surgery. Most patients can wear a new, supportive shoe immediately. A surgical shoe can also be used.

Make sure the collar of the shoe does not rub against the incision.

The patient should begin taking a NSAID immediately. They will likely need a 2–3 month prescription.

Encourage patients to discard all older, worn-out shoes! Worn-out shoes could lead to device displacement or increased pain due to over-supination.

Lots of ice/elevation (15–20 minutes per hour when awake) is strongly advised to decrease swelling and inflammation.

Each patient and each foot will vary in the post-op recovery following an EOTTS procedure. One foot will heal faster and with less pain than the other. Some patients return for their follow up appointment five to seven days post-op wearing regular shoes with minimal discomfort. Other patients present to the office using crutches. Every patient has a different pain tolerance. The amount of post-op discomfort varies depending on the:

- amount of correction achieved with the implant
- pain tolerance of the patient
- post-op compliance of the patient
- effectiveness of the anti-inflammatory and pain medication

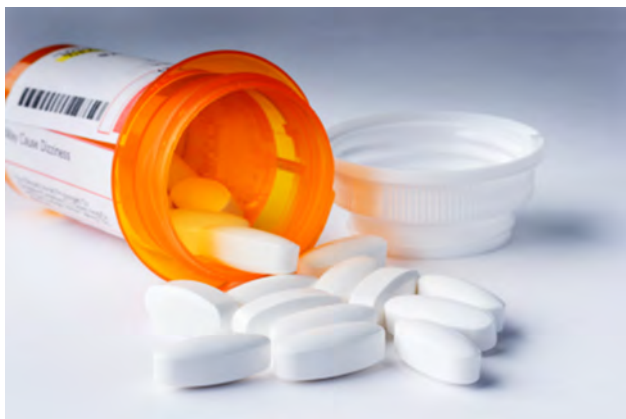The size of the implant inserted does not necessarily predict post-op discomfort: using a larger implant does not cause more pain than a small implant.

*Do **NOT** wear old, worn shoes!*



First 24-48 Hours

The surgical site should be numb for 6 to 8 hours after the surgery. The patient should take the pain



medication before there is pain. Otherwise, as soon as the patient feels a tingling sensation to the surgical site, the pain medication should be taken. It is very helpful to have the pain medication in the patient's system prior to the local anesthesia losing its ability to numb the foot. If a patient waits until the pain is present, it will take longer for the pain medication to work and the patient will experience a more painful post-op course. Patients who take the pain medication while the foot is still "numb" will have a better transition from "numb" to "not-numb."

THE LEADING CAUSE OF POST-OP PAIN IS INFLAMMATION. It is recommended to use an anti-inflammatory medication on a regular basis for up to 6 to 8 weeks. Everyone responds differently to the anti-inflammatory medication(s). If the patient takes the anti-inflammatory medication and there is no relief, then most likely the anti-inflammatory is not "working" for them and the patient should be given a different one. Also, a 5-day course of low dose steroid medication may also aid in decreasing post-op discomfort.

Even though it is relatively safe for the patient to walk on their foot, they should still stay off the foot as much as possible. Initially, the foot will feel great; it is numb. The more walking the patient does, the more inflammation and trauma they are causing

to the surgical site and the more post-op pain they will potentially experience. During this initial post-op period they should use crutches or a walker to stay off the foot.

The patient should elevate their foot whenever possible. When the foot is on the floor or in a dependent position, gravity will pull the normal fluids



in their leg down to the foot and ankle. The fluid will cause swelling which expands the incision and leads to increased pain and the possibility of pulling the incision open. This edema will potentially delay healing and recovery. Elevation will decrease the swelling, thereby speeding up the recovery.

Also, it is very important for patients to pay attention to what they eat or drink during the recovery period.



Many patients, since that are just sitting or laying down for 10 to 14 days, will consume salty foods, become thirsty and drink large amounts of soda (high in sodium content) or other liquids. Salt and fluids are NOT a good combination. Salt is a magnet for fluids, it

causes our body to retain fluid and leads to significant edema. **A very low salt diet and a decrease in fluid intake is recommended.** This will help to decrease

the post-op swelling. It may be necessary to prescribe a low dose diuretic for up to a few weeks until the edema is resolved.

Ice is a very effective post-op tool. The majority of post-op pain is due to the inflammation. Applying ice to the outer ankle 15 to 20 minutes per hour helps reduce inflammation and pain. Remind the patient to never apply the ice directly on the skin.



A bag of frozen peas or corn conforms to the ankle



better than a bag ice cubes. Ice should be applied to the surgical site for up to 6 to 8 weeks.

3 to 6 days Post-Op

If **HyProCure®** was the only procedure performed, it's recommended that the foot/ankle dressings be removed 3 to 4 days after surgery. **THE SECOND MOST COMMON CAUSE OF POST-OP PAIN IS A TIGHT DRESSING/BANDAGE.** Since this procedure is performed through a very small incision, only an adhesive bandage is required to cover the incision.

Also, when the dressing is applied, the patient usually has to wear a post-op shoe when ambulating. **THE POST-OP SHOE IS THE THIRD MOST COMMON CAUSE OF POST-OP PAIN.** By removing the dressing, a more comfortable shoe can be worn.

Once the dressings are removed, the patient is allowed to shower. The adhesive bandage must be applied to the incision during the shower and must be changed after the shower. The foot should not be soaked until the incision is completely healed.



During this period, the patient will experience a lessening of the post-op soreness; severe pain should not be a factor, unless the patient over-did-it. The patient's confidence is starting to grow that they can put more weight on their foot. It will still take a few days for the next decrease in post-op pain period. Ice remains very important: It should be applied at least twice per day, in the afternoon and evening.

Once the dressings have been removed, the patient is allowed to return to somewhat normal shoes. Here are a few very important tips regarding shoe gear.

First, the outer collar of the shoe should not rub against the incision, as this will irritate the skin and cause a superficial inflammatory reaction that could lead to wound dehiscence. Next, inspect the shoe heels for excessive wear. Since this is the major contact point between the foot and the ground, there is a major force applied there which wears out the back of the shoe. If the patient goes back to wearing the same shoe it could lead to excessive twisting in the subtalar joint and the repeated forces could displace the stent.



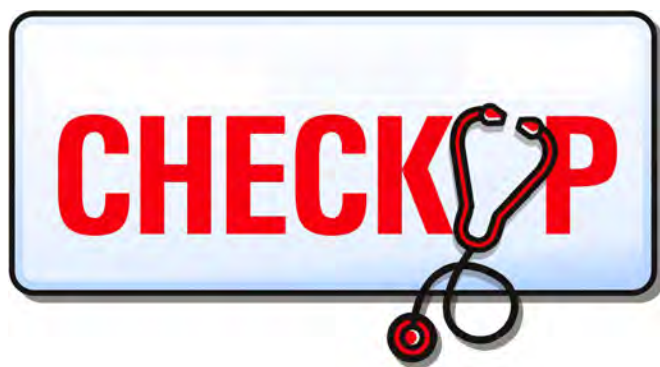Furthermore, a laterally worn out heel could also lead to excessive strain to the already strained tissues on the lateral side of the ankle joint. The patient would complain of a sprained ankle feeling.

The ideal shoe for a patient after surgery:

- is wider than the bottom of the foot so that it provides good support
- does not rub up against the incision
- does not have a worn heel
- and can allow for slight changes in swelling.

7 to 10 Days Post-Op

Within 10 days, the patient should have returned to the office for a check of the surgical site and to follow

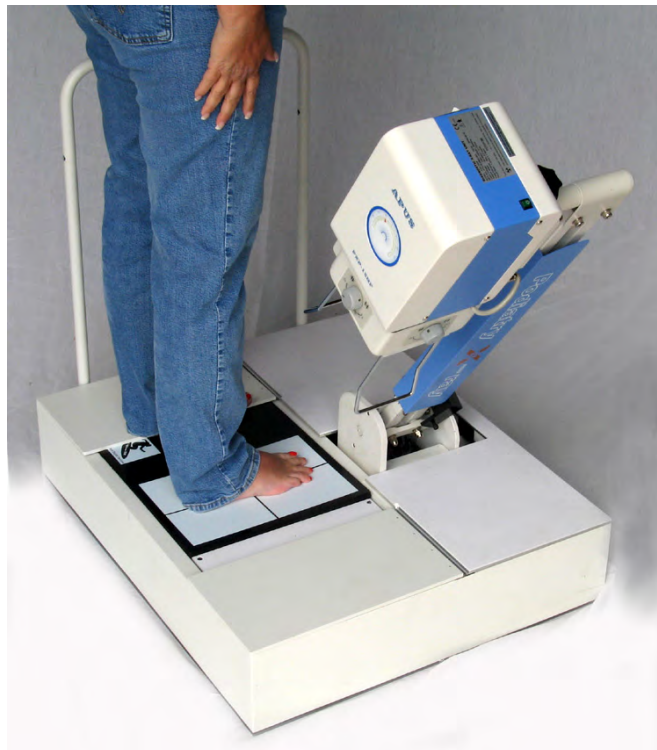

up with any other questions or concerns. Usually by the 10th day there is a significant improvement in the ability to walk. The area around the incision is still tender and inflamed making it difficult to walk “normally.” Some patients will walk in-toed or may walk on the outside of the foot. Walking on the outer part of the foot may cause the implant to get displaced or dislodged. As the inflammation decreases, the patient will be able to walk on the bottom of their foot.

During this time period there is an overall decrease in the post-op inflammation. Ice doesn't have to be used as frequently although it is still indicated in the evening and before going to bed at night. Patients will find walking easier than the first few days. Anti-inflammatory medication should be taken on a regular basis.

2 to 3 Weeks Post-Op

This is the time period to take post-op weight-bearing images of the foot/ankle. Weight-bearing images are



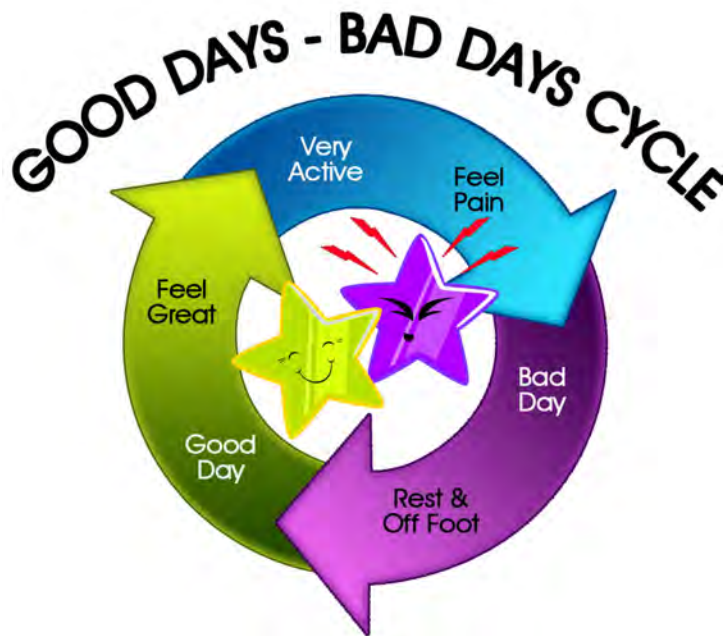essential to verify the correction achieved from the surgery. Before this period the patient may not be able to stand with their foot flat on the floor.

The post-op images should not be taken until the foot can be flat on the floor or otherwise the images will not give an accurate foot position or placement of the implant in the sinus tarsi. Due to the inflammation of the lateral tissues, the patient will want to hold their foot in a more supinated position. This is because the more pressure they put on their foot, the more the compression against the inflamed tissues. This would then falsely indicate an over-correction even though it is an accurate post-op result. If the desire is to make sure the stent hasn't shifted position outside of the sinus tarsi it is okay to take images sooner just keep in mind the “over-corrected” positioning of the talus.

Sutures, depending on the healing rate of the incision may be able to be removed, if using non-absorbable sutures. Sometimes it may take up to 4 weeks to

remove sutures. This area has a lot of pulling and stretching and it is better to leave the sutures in place longer than to remove them too soon and have the incision gap open.

Patients may experience a “Good Days - Bad Days” cycle. Since the inflammation is decreasing, they will get out of bed in the morning expecting pain, however their foot feels good. So they are more active than



the day before. The increased activity increases the stretch on the soft tissues. That night the overstretched tissues contract and when the patient gets out of bed the next morning there is increased stiffness from the previous morning. The pain will limit their activities this day and so the soft tissues recover from the overuse trauma the previous day.

The following morning the patient gets out of bed and this time has less pain since they took it easy the day before and so on. This will continue to occur until the pain finally subsides. It is different for every patient and every foot is different. Some patients may not experience this.

Finally, this is a crucial time for the tissues to adhere to the stent, locking it within the sinus tarsi. If displacement of the stent is going to occur, chances are it will happen within the three week period post-placement. There is less than a 1% chance of the stent displacing after three weeks.

The patient should limit their activities as far as any significant twisting of the subtalar joint. Normal walking is fine; any excessive chronic motion could lead to the stent displacement. It is important to make sure the patient is



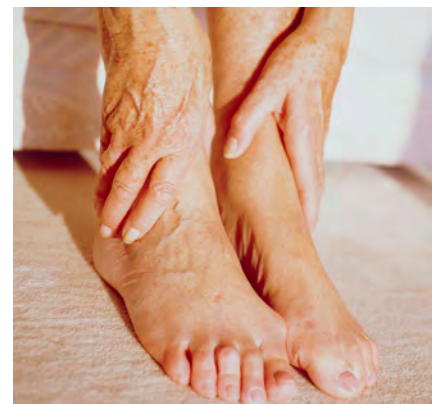wearing a good shoe that is not worn out on the outer back of the heel – this cannot be over-emphasized.

4 to 6 Weeks Post-Op

During this period the patient will be able to increase their activity level. The soft tissues within the sinus tarsi, especially within the canalis, will surround the implant to help hold it in place. The patient should be able to perform most activities during this period. However, they will still have ankle soreness and will most likely have soreness walking up and down stairs. Walking down stairs is harder since there will be more pressures on the tissues.

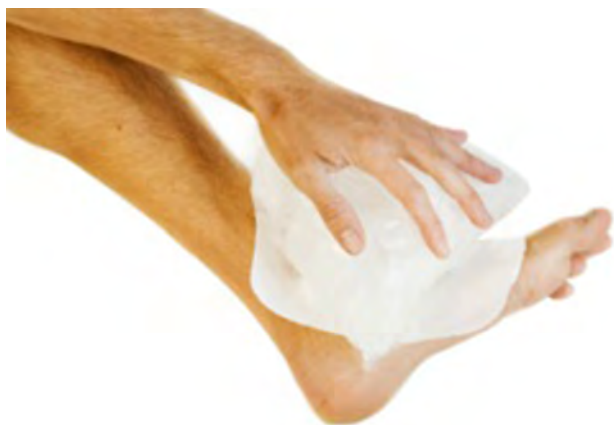The patient may develop a "Sprained Ankle Syndrome." This is a potential post-op symptom of pain to the front of the outer ankle bone. The pain comes from stretching out the anterior tibial-fibular ligament.

This develops because the sinus tarsi was closing abnormally which leads to a contracting of the ligament; now that the implant is in place there is a stretch placed on the ligaments. Patients with this condition will experience pain when they first get out of bed in the morning or after they have been sitting for a while and get up to walk. Usually the pain subsides within a few minutes.



A cycle develops where the ligament is stretched during walking/standing and when one sits down the stretch is taken off the ligament and it will then contract, so that when one starts to walk/stand again, there is pain due to the stretching out of the ligament. If there is significant pain, care must be taken to treat this syndrome. This can be the most difficult part of the recovery.

Not all patients experience this temporary soreness. There will be some patients whose ligament adapts to the new alignment and therefore may not tolerate the correction, resulting in either downsizing or removal of the implant. Patients who have suffered multiple or severe lateral ankle sprains are more susceptible to this condition. "Sprained Ankle Syndrome" needs to be aggressively treated. First check what shoes the patient is wearing, as improper or worn footwear is the main reason for the overstretching of these tissues. If the patient has good shoes and if there is significant pain to this area, **a post-op steroid injection should be given, as well as continued oral anti-inflammatory medications, and regular ice therapy**

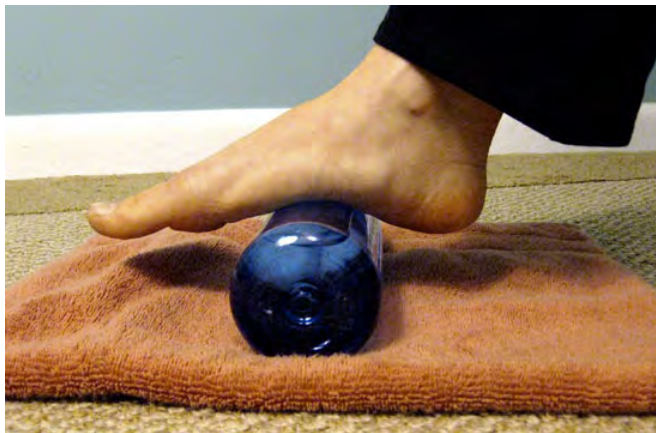

with local massage. Sometimes, physical therapy is necessary to aid in the adaptation of this ligament.

If the patient is experiencing "Sprained Ankle Syndrome," it is important for them to limit prolonged standing or walking. There is no way to predict who will develop this condition and it may not develop in both ankles. Ligaments and tendons take the longest of any structure of our body to heal due to their limited blood supply. Therefore, it is possible that it may take 4 to 6 months for the ligament to finally "stretch-

out." If there is no improvement after 6 to 8 months of conservative therapy, it is likely that the patient's ligament will not get "stretched out" and the implant should be downsized or removed.

Another symptom that may develop up to this point is a mild case of plantar fasciopathy, but it is mid-arch as opposed to insertional. Since the biomechanics have been restored to the foot, a new strain may be placed on the mid-substance of the plantar fascia. If this develops, it will usually resolve within a week or two. Rolling the foot on a frozen water bottle will help with



this as will wearing good supportive shoes, versus flat shoes such as flip-flops or sandals.

Patients may also develop soreness to the top of the foot and the front of the ankle. This is due to the new forces acting on the tendons and ligaments to this area. Ice will be very beneficial; the soreness will continue to resolve without any problem. A strain may also be felt to the extensor retinaculum, but within a few weeks at the latest this will self-resolve.

2 - 3 Months

The soft tissues should almost be fully adapted to their new function and there should be a significant reduction in post-op soreness. There should be minimal limitation of patient activity level at this point. Pain/soreness may be present when the patient gets out of bed in the morning. If patients do experience this discomfort, they should continue to take anti-inflammatory medication and should be icing the area for 15 to 20 minutes before bed. Their shoes should

again be inspected inside and out to make sure they are not worn out.

Patients who stand/walk for a living will have a longer than normal recovery. The reason for this is due to the extended periods of time a stretch is placed on the soft tissues. Anyone else will have the chance to sit and rest their feet to eliminate the extra stress to the soft tissues. Patients with jobs that require prolonged standing and walking will need to arrange to take short breaks to ice the soft tissues if they become sore. Therefore, special care needs to be taken for these patients. They will need to treat themselves like a major all-star athlete. After a pitcher has pitched a baseball game, their shoulder is wrapped in ice to decrease the inflammation on the soft tissues. Likewise, patients need to ice their foot whenever they have a chance during the day, when they initially get home from work and before they go to bed. It may take several more months before their soft tissues adapt to the new strain. Frustration may “set in” and these patients will need lots of encouragement. Remind them of the “big” picture and how it is better to go through this than through more aggressive options such as knee, hip or back surgery which might now be avoided.

4 - 6 Months

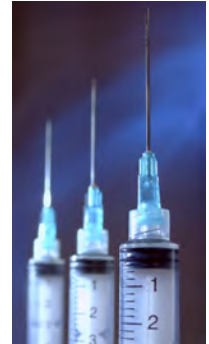The tendons and ligaments should be used to the forces acting on them. The soft tissues should be stretched out and the majority of post-op discomfort should be resolved. Some patients will still be experiencing soft tissue adjustments. Don't get disappointed if there is still discomfort. Remember the stent has repositioned the foot, changing the biomechanical forces acting on the foot and leg. It just may take some time for the foot to adjust.

6 - 8 Months

There should be no limitations and minimal discomfort. If significant discomfort is still present, most likely there may be an inability for the soft tissues to adjust to the new position. It is very important

to aggressively treat this. A strict regimen of anti-inflammatory medication should be prescribed. Try different classes of anti-inflammatory medications until you find one that's effective for the patient. A low dose oral steroid such as a Medrol Dose Pack with continued ice applications should also be considered.

At this point, you should have given up to three pin-point superficial steroid-anesthetic injections to the site of the most pain and inspected the patient's shoe gear. If after all of these measures the pain is still intense, this means the patient will not tolerate the correction and the options are either downsizing or removal of the stent.



Again, ligaments and tendons take the longest of any tissue in our body to heal because they have limited blood supply. That is why we need to aggressively attack this problem with as many different modalities as possible:

- Oral medications for a systemic approach;
- Steroid injections bathe the tissues to help on the periphery of the tissues;
- Anesthesia in the injection temporarily stops the pain cycle;
- Ice helps to decrease swelling and numbs the area as well as decreases nerve conduction;
- Ultrasound and physical therapy could also be beneficial.

1 Year

After one year there should be no residual complaints. An occasional twinge may be normal.



NOTE: If the EOTTS-HyProCure® recipient develops discomfort after they have “healed,” the most likely cause of the soreness is faulty shoe wear. It may be a good idea to check device placement.

This page intentionally left blank.

Post-Operative Pain Management

One of the biggest fears about undergoing a surgical procedure is pain after the procedure. Pain can be subdivided as acute or chronic. One of our goals as surgeons is to make our patient as comfortable as possible after a surgical procedure and eliminate or reduce pain as soon as possible. Following are a few suggestions to help our patients after undergoing an extra-osseous talotarsal stabilization procedure (EOTTS).

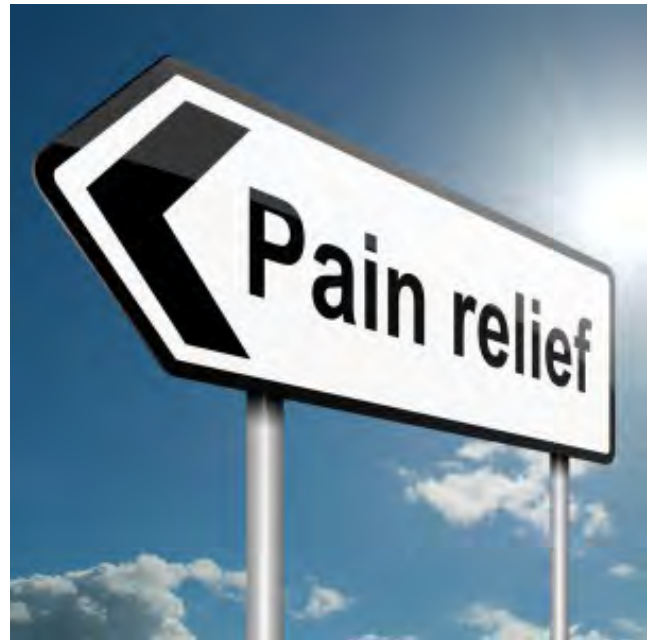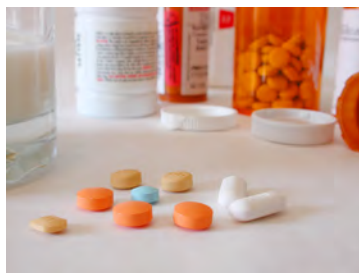Acute pain is experienced after the local anesthetic has lost its control over the associated nerve fibers. Pain medication should be taken prior to the loss of the anesthetic effect. This way there will be a gentle transition from a “numb” to “not-numb” foot.

There are many different pain medications on the market and it is important to prescribe the right one:

- Make sure the patient had no allergic reactions to previous pain medications;
- Find out if the patient had any bad experiences from previous pain medications, i.e. nausea, vomiting, or other problems;
- Ask what previous pain medications worked for them and which did not.

Patients should “feel” a difference after they take the pain medication. If there is no pain relief, it means that the medication prescribed for them is “not working.” Inform the patient to contact the office so different medication can be prescribed and hopefully it will be more effective.

Please note that patients often don't mention pain because they think that the medication is “working,” but assume that their pain is just too high for the medication to combat. However, this is simply not true. **The pain medication should relieve the pain.** It needs to be a standard part of



our follow up protocol to ask our patients how well the pain medication is working for them.

Patients must remember that the pain medication can act as a double-edged sword. It will mask the symptoms of pain, but it does not eliminate the source of the pain. Patients may fall into the “pain pill cycle.” This is what happens when the patient is too active and develops enough pain to warrant a pain pill. The medication masks the pain so the patient becomes more active, further stimulating the nerves leading to more pain. Once the pain medication wears away, there is increased pain so more pain medication is taken, leading to more activity, leading to more pain. It is better to limit the pain medication for the first 24 to 36 hours, after which it should only be used for severe pain. The patient should feel the warning signs that they are being too active and should “listen” to their body and limit their activity.

As previously stated, pain medication only masks the symptoms, while anti-inflammatory medication will help to reduce what causes the pain in the first place. Anti-inflammatories are very effective in reducing the effects of the inflammation systemically. Just like the pain medication, make sure that the anti-inflammatory is effective for that patient.

Again, the patient could be taking the pills, but not experiencing any pain relief. Make sure to follow up with them about pain levels and prescribe different medications as needed until one is found that relieves the symptoms.

The cause of post-operative pain is due to the trauma inflicted during the procedure. This leads to acute inflammation. Addition of a steroid, typically dexamethasone phosphate, into the local anesthetic mix can be administered prior to the procedure to decrease the inflammatory reaction that is about to take place. There is no worry about the steroid interfering with the healing process. Also, use a long-lasting anesthetic; the longer-lasting, the better. There is no need to use a short-acting anesthetic if the procedure is being performed under twilight sedation. By the time the foot is prepped, the anesthetic should be working.

Immediately after the surgical procedure, the patient should limit further trauma to the surgical site. The more the area is irritated by walking and movement, the more inflammation will develop. There is a purpose for this reaction from the body, so we must allow it to occur and it will subside if we cooperate with it. The acute period lasts for the first 3 to 5 days and there will be a continued decrease in the inflammatory reaction until 7 to 10 days following the procedure. However, if the area is further traumatized, this will lead to a longer duration.

There are several additional modalities that can be used to help reduce the inflammatory reaction in addition to limiting walking after a procedure. Ice is a



simple post-operative device to reduce inflammation. Patients should use this as much as possible during the recovery from a surgical procedure.

Elevation and decreased weight bearing to the operative limb are also very beneficial. Elevation decreases the amount of edema caused by gravity. The nerves in the area of the procedure are going to be very sensitive and elevation helps to decrease the gravitational pull on the fluids in the body so they don't pool in the incision area.

The second most common cause of post-operative pain is a tight bandage. As the EOTTS incision is only 1.5 cm long, there is no reason to use a large, tight or restrictive dressing. Make sure the post-operative dressings are not applied too tightly and that there is room for some swelling; otherwise the dressings will constrict the limb and produce even more pain.

After three days, the surgical dressing should be removed. At this point, only a dry, adhesive bandage is needed to cover the incision area. The incision should be kept dry. As early range of motion is a benefit, patients can begin to stretch out the soft tissues once the surgical dressing has been removed.

Transitional Pain Management

After 5-7 days, the acute phase of pain has subsided and the patient is now entering a transitional period which will either result in resolution of the pain or entry into a chronic pain cycle. Here are some hints that will help achieve the most positive results:

CONTINUE ICING

After walking, the soft tissues are over-stretched and ice will help decrease the swelling and pain. The patient should wrap a bag of frozen peas or corn in a moist dish towel and apply it to the area for 10 to 15 minutes several times a day. Elevation during this period isn't going to be very helpful, but will at least have the patient off the foot for the period when they are elevating.

Transitional Pain Management (continued)

WEAR PROPER SHOES

Anti-inflammatory medication, icing and elevating won't be effective unless the patient is wearing the proper shoe - improper shoes can be a major source of irritation.

A stiff post-op shoe can lead to discomfort since there is usually no bend to the shoe. This results in pain since the foot cannot adapt to the unstable environment. Typically, once the bulky dressing is removed, the patient will do better with a sneaker or other shoe as long as it doesn't irritate the skin incision.

Additionally, we don't want the patient to return to an old worn out shoe. Worn shoes place a strain on the soft tissues of the foot and ankle and this can lead to chronic pain. Make sure the patient is wearing new shoes to lessen the excessive strain.

SOFT TISSUE REACTION

Soft tissue strain is very important to understand. Due to the repositioning of the subtalar joint, certain tissues that were overstrained will now be restored to their normal function. Meanwhile, other soft tissues that have been "under-strained" will also be put to their normal function. In other words, the posterior tibial tendon will not have the same excessive forces acting on it and the extensors will have more.

Additionally, temporary plantar fasciitis could occur. If it does, the strain is usually mid substance and is easily resolved with conservative measures. Again, this is another period of adjustment that will either dissipate or will lead to a chronic condition. The sooner treatment and attention is directed to the condition, the quicker resolution of the symptoms will be accomplished.

GOOD DAYS, BAD DAYS

After seven to ten days of limiting their activities to the bare minimum, the patient will get "cabin

fever" and will start wanting to be more active. This leads to a phase of "good days & bad days" – a cycle of increased activity with increased pain followed by decreased activity with reduction in pain.

The patient's rest and inactivity reduced their pain and discomfort, so they increase their activity level more than what they should. When soreness develops, the patient immediately decreases their activity level and applies ice and elevation to decrease the inflammatory reaction that they "sparked."

This is followed by increased discomfort when the patient gets out of bed the next morning. So they decrease activity for the day. Little by little, depending on how they "listen" to their body and follow the post-operative advice, they will have more "good" than "bad" days.

Patients who continue to increase their activity level regardless of the pain will present to the office with generalized discomfort, non-specific complaints of "it hurts here one day and there the next." When discomfort develops in one part of the foot, compensation occurs and the gait is altered; this can place additional strain on other structures of the foot causing pain as described above. This is a continuation of the adjustment period.

It is possible for patients to have increased soreness several months after surgery. The reason for this is that the patient has become increasingly more active. This increased activity will cause an increased strain on the soft tissues, which have to adjust to the "new" foot position.

A good example is someone who is used to running a mile a day then starts running five miles a day then twenty miles a day. There will be an adjustment of the muscles to their workload. The same will be true once the talus is repositioned on the calcaneus. This is a temporary situation and will eventually subside.

CHRONIC PAIN

If the patient has had chronic pain for six months with no relief from oral medications, injections and proper shoes, then most likely the soft tissues are

Transitional Pain Management (continued)

not going to adjust to their new position. At this point, both the patient and you are frustrated with the outcome. Unfortunately, there is no way to predict when this will occur.

The treatment options are relatively straightforward:

- Downsize the stent size – this will decrease strain on the tissues and possibly reduce the pain
- Remove the stent completely – this will remove the pain, but the correction achieved will be lost.

Ultimately, the goal is to eliminate the core etiology of the patients' deformity, not to just prescribe pills to mask the symptoms. This amelioration of the symptoms without eliminating the problem has contributed to the current crisis of healthcare.

EOTTS will reposition the talus on the calcaneus, thus eliminating excessive motion and the abnormal forces acting on the soft tissues that will lead to further deformity.

EOTTS Troubleshooting Guide

The odds are that at some point, one of your *HyProCured*® patients will experience prolonged pain or require either a revision or permanent removal of their sinus tarsi stent. As with any surgical procedure, there is always the possibility of a complication. However, as a minor procedure, one benefit of EOTTS is that the possible complications are also minimal and, for the most part, have relatively simple solutions. Every attempt should be made to discover the cause of a patient's discomfort or dissatisfaction and provide an appropriate solution. Removal or revision should only be considered if other solutions to alleviate the pain/concern have been unsuccessful. The published removal rate of *HyProCure*® as a stand-alone procedure is 6%, proving that there are no guarantees of 100% success rate.



There are several reasons why a sinus tarsi stent may require removal, including:

- Prolonged pain due to inadequate soft tissue adaptation
- Device displacement
- Over/under-correction
- Failure to achieve the desired result/correction
- Psychological disturbance

The following text provides suggested guidelines to manage and/or prevent these issues.

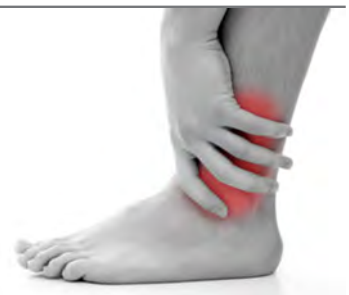When a *HyProCured*® patient presents with pain related to the device/correction, rather than the post-op pain from the actual surgery, the most likely cause is pain secondary to lateral ankle ligament strain due to the repositioning of the talus. In accordance with Davis and Wolff laws of tissue adaptation, **contracture of the lateral ankle ligaments may require an extended time to adjust to the new strain.** Not all *HyProCured*® patients experience this problem. Patients who have experienced chronic ankle sprains will be more susceptible. The overwhelming number of patients will respond to conservative measures; however, there will be a small portion that will require either a smaller sized stent or permanent removal of the device.

Ankle Pain

If a patient presents with complaints of lateral ankle pain, the following measures can help speed ligament recovery and reduce pain.

INSPECT PATIENT SHOES

Check the patient's shoe-gear. **A worn-out shoe is the leading cause of prolonged pain following the EOTTS procedure.** Ask the patient to bring in every pair of shoes that they wear for your examination. We naturally land on the posteriolateral aspect of the shoe and eventually this wears out that portion of the shoe. This leads a compensatory over-supination of the hindfoot, producing excessive supinatory strain to the anterior talofibular ligament. Ask the patient to point to the spot where the pain is occurring. If they point to the area in front of the lateral ankle malleolus (see figure), then not only do we need to look at the outer side of the heel, but also inside the shoe. It is possible that the inside is also worn out.



EOTTS Troubleshooting Guide (continued)

Pain Management

The duration and severity of the lateral ankle discomfort determines the aggressiveness of the treatment:

Mild Pain

A mild case should first be treated with proper shoe gear (see above), ice to the site of discomfort several times a day (15 minutes/hour when possible) and oral anti-inflammatory medications.

Moderate to Severe Pain

If the pain is moderate to severe, injection of a long-lasting anesthetic mixed with a short-acting steroid should be considered. The patient should be seen back in the office within 1-2 weeks and a second or third injection may be necessary.

Chronic Pain

If after three injections and six months of conservative care there is no improvement, then the patient will most likely require a revision or removal.

IMPLICATIONS WHEN THE FIRST OF TWO FEET HAVE BEEN CORRECTED

It's very important for patients to understand that they will have increased pain following their first *HyProCure*® surgery if their other foot still needs correction. Uni-



lateral EOTTS procedures will place an increased strain on the foot with the new talotarsal stabilization. At this point, the contra-lateral limb still exhibits talotarsal displacement, which exacerbates the strain to the stabilized hindfoot. For comparison, imagine wearing glasses with one clear lens and the other with a prescription correction, or balancing the tires on one side of the car, but not the other.

If a patient presents with bilateral talotarsal displacement, we recommend that both feet be corrected, one foot at a time, with the understanding that the first foot will not be pain free until the second foot is *HyProCured*®. It is very important to perform the EOTTS procedure to the contra-lateral limb as soon as the patient is able to bear full weight on their *HyProCured*® foot. It is **NOT** recommended to wait for the *HyProCured*® foot to be pain-free before scheduling EOTTS surgery for the second foot.

PROLONGED STANDING/WALKING FOLLOWING SURGERY

Also, it is important to understand that patients who have standing/walking jobs will have longer recoveries as it will take much longer for their soft tissues to adjust. This is due to the chronic and/or prolonged strain on the tissues. Individuals who can limit their walking/standing will heal/adjust faster since their soft tissues are not subjected to those same forces. This is an important fact that needs to be discussed with potential surgical candidates. Emphasize that their recovery could potentially be 2 to 3 times longer, due to the amount of standing/walking they are required to do.

Stent Displacement

When you review the radiographs from a recent EOTTS procedure and see that the stent has shifted from its initial placement in the operating room, questions such as "what happened?" or "why did this stent displace?" go through your mind. The truth is that displacement has always been a leading problem with extra-osseous talotarsal stabilization devices. *HyProCure*® was specifically developed to reduce the rate of displacement, but it can and will occur - even if you perform the technique perfectly.

EOTTS Troubleshooting Guide *(continued)*

EOTTS is a very unique surgery with a very unique set of potential problems. Remember that the **HyProCure®** stent is not a screw threaded into the bone. Instead, these stents are placed into the sinus tarsi and the threads provide a way for the soft tissues and ligaments to help hold onto the stent as the patient heals.

Remember, intra-operative, non-weightbearing radiographs may show the stent in a different position than may be observed later post-operatively in weightbearing radiographs.

The patient's surgical consultation should have included a warning that displacement of the device could potentially occur. If a stent does displace, the patient should be told truthfully that the stent is either partially or fully displaced.

The most common reasons for stent displacement are as follows:

- Inadequate placement - the threads were not properly placed within the canalis portion of the sinus tarsi
- Not completely cutting the soft tissue fibers within the canalis portion of the sinus tarsi
- Inadequate trial sizing, which leads to the insertion of an undersized stent
- Patient wearing worn-out shoe when walking
- Inadequate patient compliance – the patient was too active too soon
- Patient injury/trauma – such as severely twisting the ankle
- Performing bilateral stent placements at the same setting – this increases the chance of displacement
- Patient's bony anatomy
- Stent is seeking the best location

The most common cause of HyProCure® displacement is improper placement.

The **HyProCure®** stent is not inserted at the same angle as the other sinus tarsi stents. **HyProCure®** follows the direction of the sinus tarsi from anterior-lateral-distal-inferior to posterior-medial-proximal-superior. Other sinus tarsi stents are placed from lateral to medial.

When inserting the **HyProCure®** stent, remember the angle and head to the posterior aspect of the medial malleolus. You should also check the placement under fluoroscopy. You cannot always rely on pushing the stent in as far as it will go, assuming that the tapered portion is abutting the lateral part of the canalis.

Additionally, do not fully rely on the guide wire. It is possible to have the guide wire aimed from lateral to medial as the wire is under the neck of the talus and not in the canalis portion of the sinus tarsi. **The definitive test to check placement is fluoroscopy/ radiographic imaging.**

Another common cause of stent displacement is the inadequate cutting of the fibers within the canalis portion of the sinus tarsi.

Pre-operatively, these fibers are stretched and serve no function in patients with talotarsal displacement. Cutting them allows the threaded portion of the stent to be inserted in the canalis portion of the sinus tarsi, and then those fibers will “heal” back together and incorporate the stent within the fibers, giving the stent more stability.

Incomplete transection of these fibers may allow the stent to look like it was placed deep enough into the sinus tarsi on fluoroscopic imaging; however, upon weightbearing, those uncut fibers can act as a sling-shot - pushing the stent laterally a few millimeters or more.

EOTTS Troubleshooting Guide (continued)

Cutting the fibers within the canalis portion of the sinus tarsi is a blind procedure. Use curved tenotomy scissors. Make sure the curve is heading posteriorly, not anteriorly. It will feel like you are cutting small rubber bands. It is best if the scissors are sharp; if they are dull, you go through the motion of cutting them, but the fibers remain intact. Also, you should be able to feel the tips of the scissors medially. It is recommended to make three cutting passes:



1. Cut the bands in the central part of the canal
2. Cut under the neck of the talus
3. Cut on the floor of the canalis.

Don't remove the cut fibers because they will heal back together, fixating the threaded portion of the stent within the canalis tarsi.

When trial sizing, make sure to fully load the 4th and 5th metatarsal heads. It's possible to end up with a smaller size stent than what is required if the 4th and 5th metatarsal heads are not fully loaded. As a result, the undersized stent could potentially "move around" within the sinus tarsi before the fibers have healed. Make sure to put your body weight into the foot when trial sizing. Also, make sure that the trial sizer is positioned correctly. This should be checked under fluoroscopy.

Every patient has different thresholds of pain after surgery. If a patient has a high pain threshold and becomes too active too soon, it is possible there

could be too much force placed on the stent before it has a chance to get incorporated into the soft tissues. Again, make sure that the patient is not wearing their old, worn out shoes after surgery. A very worn shoe, especially the outer heel, would lead to excessive torque on the subtalar joint leading to stent displacement. Extremely worn shoes can completely twist the patient's hindfoot. As a result, the stent may not have a chance to get incorporated into the soft tissues and may displace.

Physical trauma to the hindfoot could also lead to stent displacement.

One patient who was pain free about two to three weeks after surgery, began jumping on a trampoline. He stepped wrong and twisted his ankle - displacing the stent. After surgically repositioning the stent, the patient stayed off the trampoline for six weeks. The stent has stayed in place ever since.



Conversely, we have also documented patients who slipped on icy sidewalks and severely twisted their *HyProCure*® foot and *HyProCure*® didn't move a millimeter out of place.

Experience has shown that it's important to perform EOTTS on one foot at a time. Recovery takes much longer when both feet are operated on at the same setting since the patient won't have one good foot to stand on or walk on.

The chance of a stent backing out with bilateral procedures is estimated at about 25%, although this number is not evidence-based. Bilateral *HyProCure*® procedures are not recommended due to the long recovery and increased chance of return to the operating room for stent placement revision.

EOTTS Troubleshooting Guide (*continued*)

However, the decision to proceed with unilateral or bilateral procedures is at the surgeon's discretion. Bilateral procedures are not a contra-indication.

If the stent has displaced even though:

- you completely cut the interosseous structures
- you trial sized correctly
- you inserted the stent into one foot at the correct angle
- the patient wore proper shoes
- the patient incurred no trauma

then it is most likely due to the patient's anatomy.

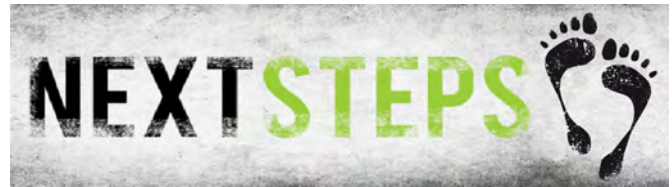HyProCure® stents come in six different sizes, suitable for patients of all ages and sizes. No surgical procedure is 100% guaranteed; the stent may possibly become displaced due to the osseous anatomy. Pre-operatively, it is impossible to know for certain that this will occur. In some cases, displacement is neither your fault nor the patient's.

If it's going to happen, stent displacement will most likely occur within the first three weeks post-op. However, it is still possible that displacement can occur later in recovery. Even if the patient was completely non-weightbearing for 4 to 6 weeks, it is still possible, due to patient anatomy, that the stent could back out if it has to "seek its own level."

Also, the longer a patient is immobilized, the longer their recovery since the soft tissues will have to get "accustomed" to their "new" foot. Limited early range of motion will speed up recovery and has not been shown to increase the chance for stent displacement.

Finally, even though you placed the stent in a technically correct position, it may shift somewhat. For instance, a bony abnormality could be present between the talus and calcaneus within the sinus tarsi and the stent may "seek its own level" to provide for the best possible correction. As long as the patient has no pain and there is no loss of correction, this technical displacement does not require post-operative correction or revision.

Course of Action for a Displaced Stent



If the stent has displaced, determine your course of action as follows:

(1) - The Stent Is Slightly Displaced

Situation Summary: some of the threads of the stent are within the canalis portion of the sinus tarsi, correction is maintained (improved from pre-op mal-alignment) and the patient either has no pain or pain consistent with a normal post-operative recovery.

No action is required. Leave the stent where it is and inform the patient that the stent has slightly shifted from its "ideal" position due to their anatomy. Since there is no pain and the correction is stable, there is no reason for a revision. However, there is a chance that it can further displace and it may need to be revised in the future. An immediate return to the operating room is not recommended unless you think the inter-osseous ligament may have been incompletely cut, or you suspect trial sizing or stent placement issues. If the procedure was performed properly, and you choose to surgically reposition the stent, the stent could re-position itself again – as it did the first time. Then the patient will have gone through another surgery without any benefit.

(2) - The Stent Is Significantly Displaced

Situation Summary: the threads of the stent are not in the canalis portion of the sinus tarsi, correction is maintained.

At this point, the stent is acting like the other stents on the market - which is still an

EOTTS Troubleshooting Guide (*continued*)

improvement. However, there is still the potential of further displacement. In this situation, the decision to revise may be difficult as the current result could go either way. For instance, the stent could be stable enough to maintain correction and there is no need for a return to the operating room, or the stent could further displace, forcing a return to the operating room. This requires a discussion between the physician and the patient and is ultimately the patient's call. It's recommended to take a "watch and wait" position; watch the foot and recheck the position of the stent. **If there is loss of correction and/or pain, then the stent needs to be re-positioned.**

(3) - The Stent Is Completely Displaced

Situation Summary: there is loss of correction from the intra-operative placement.

Clearly, the stent needs to be revised. See below.

Stent Revision and Repositioning

In the rare instance that a stent needs to be repositioned, follow the technique outlined here.

- Using the same local anesthetic as in the original surgery, open the existing incision or make a new incision over the sinus tarsi as done previously.
- Using the curved tenotomy scissors, separate the deep tissues.
- Using a pair of needle drivers, grab the lateral end of the stent, twist the stent 360 degrees counter-clockwise and you should now be able to pull it out. Place the stent in saline.
- Reintroduce the tenotomy scissors to make sure the deep tissues have been cut. If you find that there are uncut fibers, then you know this was the problem.

- Next, retrieval size and check the position of the trial sizer under fluoroscopic imagery.
- Load the foot to see which size stent gives the best possible correction. If it seems you need the same size stent as you removed, then re-insert the same stent.
- Verify placement under fluoroscopy. If it looks like you cannot place the stent as deep as you would like, you may need a smaller size. **Remember, it is better to have the stent placed deeper and possibly have an under-correction than to have a displaced stent.**
- Reapproximate the skin incision.
- Wrap the foot/ankle with a dry sterile dressing topped with self-adherent wrap.
- You might consider use of a removable cast brace for up to three weeks and have the patient limit their activity level.

Finally, make sure the patient does not put their foot into a motion that could displace the stent again. Prior to the revision, do warn the patient that there is a possibility that the stent could displace again, due to the anatomy in the space or the lack of soft tissue adherence onto the stent. It's all about patient expectations and trying to keep them as realistic as possible.

Under- or Over-Correction

An EOTTS procedure is performed with the patient non-weightbearing. No matter which design of device is used, there is no such thing as a perfect sinus tarsi stent for every single foot. The surgeon will insert the trial sizer to determine which size device would give the best correction. The foot is put through a range of motion to try and re-create how the foot would function during weightbearing. Finally, the appropriate-sized stent that would allow the normal motion to occur while preventing the excessive motion is selected and inserted into the sinus tarsi in the desired position.

EOTTS Troubleshooting Guide (*continued*)

There may be times where two sizes appear to give very similar correction; then a decision needs to be made on which size to use:

- The goal is to provide 3-4 degrees of pronation.
- If two sizes of stents seem to produce similar results, choose the smaller size.
- **It's always better to under-correct.**

Pronation is a normal foot motion; our goal is only to eliminate the **excessive** pronation.

Even though the procedure appears to have provided the best possible correction while the patient is non-weightbearing, when the patient stands, the situation may be different. Even though the subtalar joint complex is now in a better position, additional factors affect the stability of the entire foot. Instability at either the mid-tarsal joint or at the first metatarsal cuneiform joint could still allow loss of correction anterior to the subtalar joint complex. These patients may benefit from additional stabilizing procedures of the medial column of the foot.

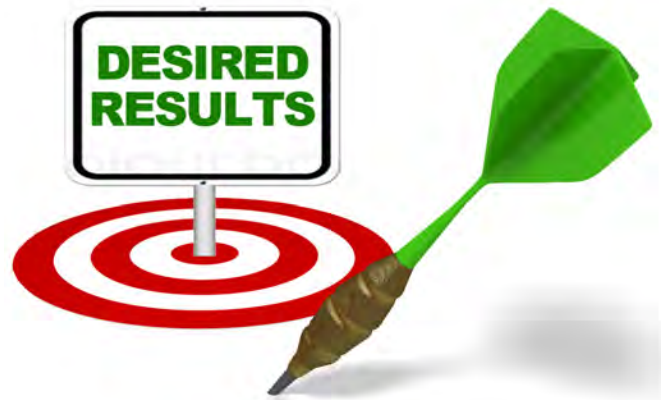For several weeks after the EOTTS procedure, the patient may appear to walk with a supinated appearance and relate a feeling of increased pressure under the lateral column of the foot. The reason for this is that during the first several weeks there will be an inflammatory reaction mixed with swelling and a fear of putting their entire weight on the operated foot. These factors resolve over time and the patient will be able to walk on the bottom of their foot.



CAUTION: If x-rays are ordered before the patient is able to put full weight on the foot, it could give the radiographic appearance that the surgeon had oversized the stent used in the patient's foot.

Failure to Achieve the Desired Result

Every sinus tarsi has different characteristics and can range in size from very narrow to very wide. It is possible that after finding the best size device and inserting it into the proper position, there will still be loss of correction. Please note that sinus tarsi devices



are held in place not only by the soft tissues within the sinus tarsi, but also by the osseous structure of the canal itself. It is possible that instead of the calcaneal portion of the canal being “c” shaped, it is flattened out by the chronic trauma of the talus grinding away on it – which can cause further instability.

Once the patient becomes weightbearing, these forces can place excessive torque on the device and since it is not stabilized by the calcaneal portion of the sinus tarsi, it may slide out of position along with the talus. If that is the situation, the patient may need a more aggressive procedure than **HyProCure®** to achieve correction.

A rare situation can arise where the patient has a talocalcaneal coalition that is not visible on x-ray. The recommendation is to always take neutral stance position radiographs and compare them with relaxed stance position radiographs to document the reducibility of the talotarsal displacement. This helps to rule out a coalition. If there is suspicion of a coalition, then order a CT scan.

EOTTS Troubleshooting Guide *(continued)*

Psychological Reaction/Rejection

Another possible rare scenario is a little-discussed reaction of a subset of patients who have a mental issue with the fact that an implant has been inserted into their body and they quite simply cannot accept it. These patients have no pain from the procedure nor do they have any limitations. They dwell on the fact that this device is in their foot to the point where it has to be removed. This occurred in 2 of the 117 feet in the published 5-year retrospective follow up study on *HyProCure*®. Even though these patients knew that the *HyProCure*® was going to be inserted into their foot, they did not know that they would not be able to mentally accept it.

Surgical Technique for *HyProCure*® Removal

- Same incision approach as in the original surgery.
- Use curved Stevens tenotomy scissors for tissue dissection (use the tips of the scissors to spread the tissues; do not cut the tissues - simply open the tips of the scissors to dissect the tissues).
- Identify the lateral end of the device.
- Use a strong needle driver or sterile needle-nose pliers to remove the stent.
- Insert one jaw of the instrument into the center of the device and clamp the second jaw on the lateral end of the device.
- Apply pressure on the instrument to clamp onto the head of the implant.
- Rotate the implant 360 degrees counter-clockwise. This releases the soft tissue adherence on the device, allowing you to then take out/pull the device from the sinus tarsi.
- Irrigate the sinus tarsi with additional local anesthetic to ensure that the deeper tissues are anesthetized.

HyProCure® Revision

If a revision is necessary, follow the steps specified in the previous section for removal, then:

- Use the curved Stevens tenotomy scissors to decompress the tissues within the canalis tarsi.
- Insert the various trial sizers to re-establish the correct size stent to stabilize the talotarsal joint.
- Insert the proper stent and verify position under fluoroscopic imaging.
- Suture the skin and apply dry sterile bandage.

EOTTS – *HyProCure*® Patient Selection Check List

- Patient is older than 3 years of age**

- Flexible/reducible talotarsal dislocation deformity with clinical and radiographic evidence**
 - Non-weightbearing exam - excessive TTJ pronation (< 6 degrees)
 - Static weightbearing exam - anteriomedial talotarsal displacement
 - Gait analysis - abducted forefoot
 - Relaxed stance position weightbearing radiographs –
 - Obliterated sinus tarsi
 - Increased talar declination angle > 21 degrees
 - Navicular drop (below ½ bisection of the cuboid)
 - Anteriorly deviated cyma line
 - Talar second metatarsal angle > 16 (AP View)

 - Neutral stance position weightbearing radiographs –
 - Open sinus tarsi
 - Decreased talar declination angle
 - Increased navicular height (above ½ bisection of the cuboid)
 - Reduced cyma line
 - Talar second metatarsal angle < 16 (AP View)

This page intentionally left blank.

Patient Clinical Examination: Be On The Look Out Check List

- Non-weightbearing exam**
 - Limited 1st MPJ range of motion
 - Hyperextended 1st metatarsal/hypermobile 1st ray-MCJ
 - Compromised medial band of the plantar fascia
 - Posterior tibialis tendon dysfunction

- Weightbearing exam**
 - Metatarsus primus varus
 - Metatarsus primus elevatus
 - Metatarsus adductus
 - Calcaneovarus
 - Equinus/pseudoequinus
 - Genu recurvatum/varum/valgum

- Gait analysis**
 - Adducted forefoot
 - Calcaneovarus
 - Equinus gait

- Radiographic evaluation**
 - General
 - Signs of a tarsal coalition – halo sign, anteatler sign
 - Congenital talocalcaneonavicular osseous deformities
 - Lower than normal calcaneal inclination angle
 - Mid-foot arthritis/exostosis formation
 - Metatarsus primus varus/metatarsus adducts
 - Comparison of RSP to NSP
 - Sinus tarsi remains obliterated
 - Navicular does not “elevate”
 - Talar declination remains > 21 (does not reduce)
 - Talar second metatarsal angle remains > 16 degrees

This page intentionally left blank.

EOTTS – *HyProCure*® Surgical Procedure Check List

- Draw landmarks on the skin.
- Inject 7-10ccs of long-last local anesthesia combined with 0.5-1.0ccs of short/intermediate acting steroid into the sinus tarsi.
- Incise the skin using a #15 blade to make a 1.5 to 2.0 cm incision centered over the sinus tarsi.
- Insert tips of curved GraMedica *HyProCure*® Sinus Tarsi Decompression Scissors into superficial tissue to create opening into the sinus tarsi.
- Ensure that the angled tips of scissors are aimed posteriorly.
- Decompress the tissues within the canalis tarsi/confirm position under fluoroscopy.
- Insert guide wire deep into the canalis tarsi (optional), check under fluoroscopy.
- Insert various *HyProCure*® Sizers until 3-4 degrees of TTJ pronatory motion is present, check sizer position under fluoroscopic imaging, AP View only.
- Insert desired size *HyProCure*® stent deep into the sinus/canalis tarsi, check under fluoroscopy.
- Remove guide wire and driver and re-check TTJ range-of-motion and final position of *HyProCure*®.
- Reapproximate and suture skin edges only.
- Apply a dry sterile dressing.

This page intentionally left blank.

EOTTS – *HyProCure*® Patient Pain Check List

- Take weightbearing DP and lateral radiographs to verify *HyProCure*® placement/position.
- Observe patient shoes – have patient bring in all the shoes they wear and inspect them for excessive lateral heel wear patterns, sometimes you need to also check inside the shoes.
- Confirm the effectiveness of oral anti-inflammatory medications (patient should feel some pain relief within ½ hour of taking the medicine).
- Consider the use of a shoe insert/OTC/custom-made orthosis to assist in the soft tissue adaptation period.
- Inject a “cocktail” combination of 1.5 cc of long-acting local anesthesia with 0.5 to 0.75cc of intermediate steroid into the superficial area of the anterior talofibular ligament. Give up to 3 injections over a 4 - 8 week period.
- Consider other physical therapeutic modalities
- If 6 – 8 months post-EOTTS there is no improvement consider downsizing or permanent device removal.



NOTE: If you suspect an “over-correction,” you must take into consideration if the patient has persistent pain in the sinus tarsi. To rule out supinatory-guarding compensatory pain, perform an injection into the lateral sinus tarsi and repeat the x-ray. Make sure the patient is standing with full weight on the foot and that they are not experiencing any pain while they are standing on the foot. An over-correction will be radiographically confirmed with a talar second metatarsal angle < 0 (negative angle) and a talar declination angle < 0 on a lateral radiograph.



ADDITIONAL CONSIDERATION: The EOTTS procedure can accomplish something that a foot orthosis simply cannot – stabilize and restore talotarsal range of motion. On the other hand, we must remember that a foot orthosis can do things that a sinus tarsi implant cannot. Many patients will benefit from the combination of an EOTTS procedure along with an arch support either temporarily or permanently.

There is no such thing as a treatment modality that works for everyone. EOTTS has its limitations, risks and potential complications.

This page intentionally left blank.

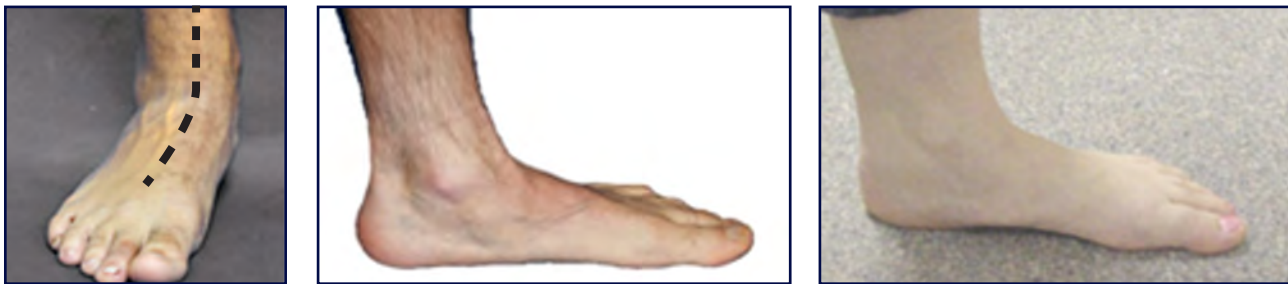Staff Resources

DP and Lateral Radiographic Comparison Technique

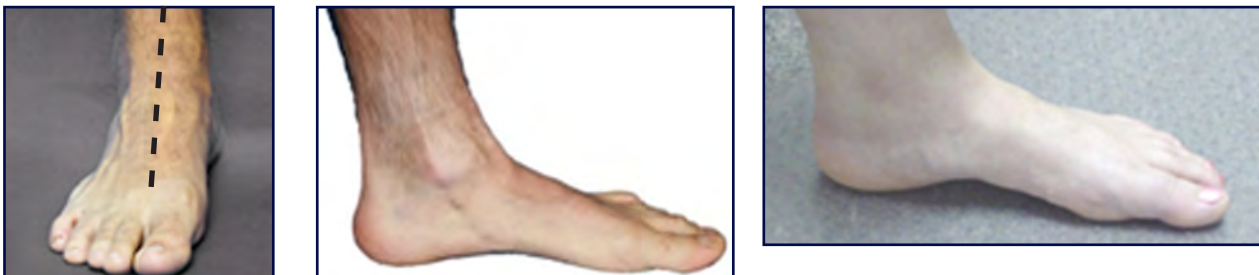Comparisons of relaxed stance position to neutral stance position radiographs are a very useful diagnostic and educational tool for both the physician and patient.

The tube head positions do not change between the relaxed or neutral stance.

Relaxed Stance Position usually looks something like:

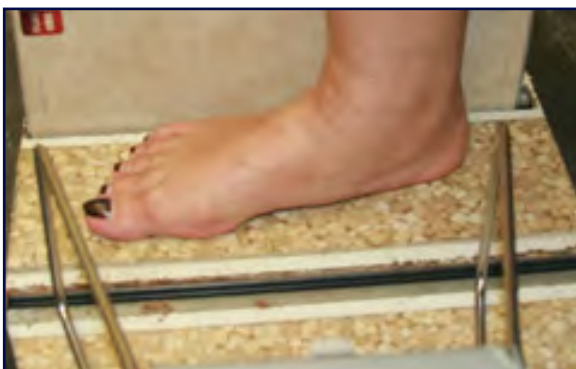

Neutral Stance Position should look like this:



Make sure that the patient doesn't over-correct/supinate their hindfoot.

Relaxed Stance Position



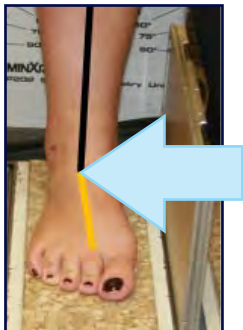Neutral Stance Position



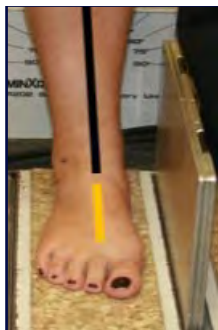Radiographic Positioning Guide

>> Relaxed & Neutral Stance Position

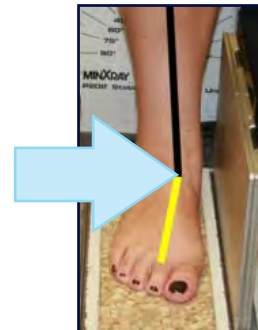Supinated Rearfoot



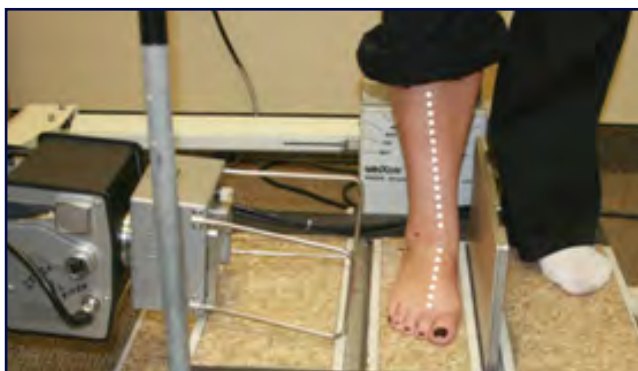Neutral Rearfoot



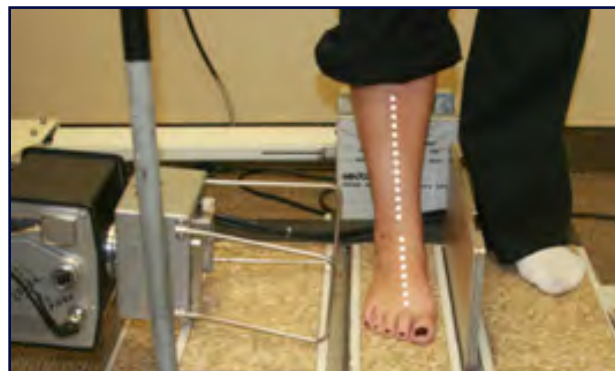Pronated Rearfoot



Lateral View: tube head @ 90 degrees

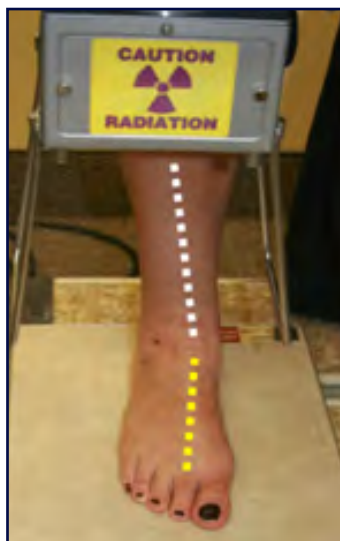

Relaxed Stance Position

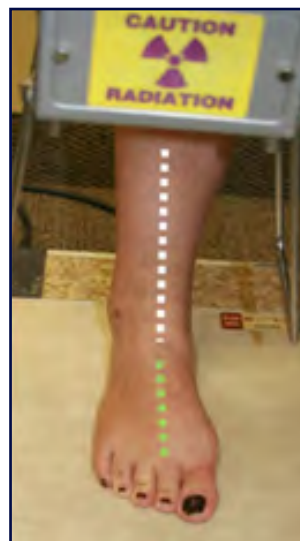


Neutral Stance Position

Relaxed Stance Position



Neutral Stance Position



AP/DP View: tube head @ 15 degrees

EOTTS - *HyProCure*® Procedure Check List

Pre-Op:

- Completed EOTTS Forms (See appendix 1 – EOTTS Consent/No Guarantee/Financial Arrangement)
- Patient should be given antibiotic prophylaxis (oral/IV if twilight sedation) within 1 hour of the EOTTS procedure and valium after signing appropriate forms.
- Patient should take an anti-inflammatory the morning of the procedure, if local only.
- Staff verifies that the *HyProCure*® instruments have been sterilized and the various stent sizes are available.
- Marcaine with epinephrine local anesthesia mixed with ½ cc of dexamethasone.
- Provide patient with post-op prescriptions.

Post-op:

- Make sure to document final *HyProCure*® placement with either intra-op fluoroscopy or post-op x-ray prior to the patient leaving the office.
- Dispense surgical/post-op shoe, crutches

OR Supplies:

- Instruments:
 - #15 blade (sterile) on scalpel handle
 - Curved Stevens tenotomy scissors (GraMedica)
 - Pick-up – Adson-Brown or Adson Forceps, surgeon's preference
 - Needle driver
 - *HyProCure*® trial sizers, guide wire and driver
- HyProCure*® implants
- 4-0 suture to close skin (surgeon preference)
- Supplies:
 - Sterile 2x2/4x4 gauze, kling, self-adherent wrap
 - Betadine/Hibiclens to prep the foot
 - Sterile ½ sheet/drape
 - Surgical shoe
 - Crutches (optional)

Benefit-Risk Analysis of Extra Osseous-Talotarsal Stabilization

Your doctor has examined you clinically and radiographically and diagnosed you as having talotarsal displacement (partial dislocation of the ankle bone on the heel bone). The purpose of this document is to inform you on your condition and to provide an overview of the benefits and risks of the suggested surgical treatment: extra-osseous talotarsal stabilization (EOTTS) procedure. This document will cover the natural progression of talotarsal displacement, the benefits of internal correction and the potential risks associated with EOTTS. Though intended to be as thorough as possible, it is impossible to predict every scenario that may occur with your treatment. This guide covers all possible complications that have been reported with at least a 1 in 1000 chance of occurrence.

Natural Progression of Partial Talotarsal Dislocation

Weight is placed on the hindfoot bones when standing, walking or running. Normally, there should be very little motion between the ankle bone (talus) and the hindfoot bones during weight bearing activities. The associated joints should remain in constant congruent contact at all times. Partial displacement or dislocation occurs when the ankle bone slips off the heel bone (calcaneus) as weight is placed on the foot. This partial dislocation leads to an abnormal shift of forces; forces that should pass through the back of the heel instead pass through the inner part of the foot. This causes excessive strain on the bones and tissues (ligaments, tendons, muscles, nerves and blood vessels) of the foot. It is only a matter of time until the excessive strain will take its toll and one or more of the tissues will become symptomatic. Every step leads to further pathological forces acting on the tissue(s) which will continue to get worse and worse.

It is important to note that the displacement of the ankle bone (talus) is not natural and will progressively get worse over time. It will also lead to pain and damage to other areas of the foot and to the rest of the body.

The tissues within the foot and ankle are not the only ones that will be affected by this deformity. There will be a chain- reaction through the entire body. When the ankle bone slips off the heel bone, it drops down and turns inward. This partial dislocation closes the natural space between the ankle and heel bones (the sinus tarsi). The ankle bone “drops out” from underneath the leg bones (tibia/fibula), forcing them to also drop down and turn inward. This places a twisting strain on the knee and can lead to excessive wear-and-tear.

The thigh bone (femur) also drops and turns inward, leading to a tilt of the pelvis. Pelvic tilt leads to abnormal twisting and turning on the spine, placing tremendous force on the small cushions between the bones of the spine, which can lead to “herniated discs.” The back muscles tighten to try and stabilize this misalignment and can become painful. Twisting in the lower back leads to twisting in the upper back in order to compensate. This leads to upper back problems and a twisting of the neck and skull.

Many people with ankle bone displacement are not even aware that their feet are misaligned since most people do not experience pain between the ankle and heel bone. However, pain will eventually show up at the weakest link to the musculoskeletal chain. Unfortunately, treatment is often focused on trying to eliminate the pain in the secondary sites without addressing the underlying deformity. Until the underlying etiology (ankle bone displacement/misalignment) is fixed, the pain will keep recurring. Imagine all of the money spent on medication and physical therapy, the time away from work and the inability to do various activities because of the pain that ensues following those activities. This deformity and the resulting diseases will even take a toll emotionally as painful symptoms won't go away and nothing helps to solve the problem(s). It may even affect personal relationships.

Overall health could also be adversely affected by a misaligned hindfoot. Painful secondary conditions will slow you down. Decreased activity leads to decreased metabolism which leads to increased weight or obesity. It has been proven time and time

Benefit-Risk Analysis of Extra Osseous-Talotarsal Stabilization

again that obesity leads to diabetes, heart disease, acid reflux (GERD), high blood pressure, sleep apnea and even several forms of cancer.

Partial talotarsal dislocation will not “self-correct.” There is a defect with the joint surfaces along with over-stretching and weakness of the ligaments and/or tendons. It is important to realize that this deformity is occurring internally above the heel bone (above the bottom of the foot). This deformity can be present without pain, but as previously stated, it is only a matter of time until a symptom develops somewhere in the body. A great illustration is an unbalanced car tire. Initially, the tire functions okay, but the more the car is driven, the faster the tire wears out. This can lead to damage to the wheel well, the shocks and struts, the alignment of the car... you get the picture. The more active someone is with a misaligned hindfoot the faster a painful symptom will develop somewhere in the body as a direct result.

Benefits of the EOTTS Procedure

The minimally invasive insertion of the *HyProCure*® extra-osseous talotarsal stabilization device into the sinus tarsi is an extremely powerful procedure. *HyProCure*® acts as a stent to prevent the collapse of this naturally occurring space while still allowing the normal amount of motion to occur. The benefits of this option are far reaching, especially when compared to other options such as padding, arch supports/orthotics or major rear foot reconstructive surgery.

Realignment of the ankle bone on the hindfoot bones decreases strain on the supporting tissues. This has been scientifically proven and published in peer-reviewed foot and ankle surgical journals. Decreased strain should prevent the progression of secondary deformities and could allow the body to “heal” itself by repairing the damaged tissues. In some cases, it is possible there is already so much damage that other surgical procedures will be necessary. However, in most cases symptoms such as soreness and pain should significantly reduce and

possibly completely resolve. Walking is improved and should be easier once swelling and pain from the procedure have diminished. There should be improved function not only of the structures within the foot but also of the knee(s), hip(s) and back.

Since it is easier to walk and exercise, the metabolism of the body is increased. Increased metabolism helps to reduce weight and therefore has a positive effect on the associated medical conditions related to obesity and a higher body mass index (BMI). Many patients have lost weight, lowered their blood pressure and lowered their blood sugar levels naturally after the EOTTS procedure.

There are also economic benefits. It could be possible to decrease the amount of prescription medications needed, especially those taken for pain management, but also those taken for conditions associated with extra weight. The improvement in health may also lead to a decreased need for medical appointments to foot specialists, chiropractors, physical therapists, orthopedists and primary care physicians. This means more time to work and less time taken off due to medical conditions.

One of the most important benefits is the improvement in quality of life. It's a shame when someone is unable to do the things they love due to their painful symptoms. Even simple things that most of us take for granted, such as shopping, walking the dog or playing with our children or grandchildren are affected. It is possible that once the EOTTS procedure is performed, things that were thought of as impossible before or just not worth the suffering that would follow are now possible without the associated pain. This internal option does not rely on external devices such as pads, arch supports, shoe modifications or braces. External options cannot prevent the displacement of the ankle bone. Secondary issues, such as a collapsing arch, may appear better when the orthotic is in use, but it is still possible that other structures are being strained. Also, it is impossible to use these all the time. Every step without the use of these devices results in maximum strain on the tissues. *HyProCure*® is

Benefit-Risk Analysis of Extra-Osseous Talotarsal Stabilization

internally placed and is always working to decrease strain. It functions no matter the weight bearing surface, such as walking/running on the beach, performing gymnastics barefoot and on and on.

EOTTS is usually performed through a small incision of less than ½ inch. It is not considered a bone surgery but a soft tissue procedure as there are no modifications made to the bone. The *HyProCure*® device is simply pushed into place. There are threads on the end of the device that serve as a way for soft tissues to adhere to this portion of the stent to anchor it firmly in place. However, if the device does need to be removed, it can be easily done, simply by releasing the tissue on-growth and pulling it out. EOTTS with *HyProCure*® can be performed by itself or in conjunction with other surgical procedures, depending on the severity of the overall foot and ankle misalignment and other coexisting deformities.

EOTTS with *HyProCure*® has been performed on pediatric and adult patients since 2004. This is not considered a purely pediatric nor an adult-only procedure. *HyProCure*® is used by foot and ankle surgeons in more than 30 countries.

Risks Associated with the EOTTS Procedure

EOTTS is a surgical procedure and is therefore subject to certain risks and potential complications. There are four main risk categories including anesthesia, surgical procedure, device and post-procedure. The risks associated with this procedure are not severe when compared to the potential risks and complications associated with more aggressive reconstructive procedures. Nonetheless, it is important to have a thorough understanding of what could potentially go wrong.

The EOTTS procedure with *HyProCure*® takes less than thirty minutes on average. Typically numbing medicine (local anesthesia) is injected into the area below the outer ankle bone, which is the least painful spot on the foot or ankle to have an

injection. Many patients are given “twilight” sedation where additional medications are given through an IV to put the individual into a sleep-like stage. Medicine given through an IV is fast-acting and safe. Although reaction to these medications is extremely uncommon, it is possible. In rare cases, a general anesthesia is required.

The actual EOTTS surgical incision is placed below the outer ankle bone, usually one index finger below the inferior (lower) edge. There are no major blood vessels, nerves or tendons in this area. An ankle tourniquet is usually not necessary since there should be very little bleeding. This is a soft tissue procedure and there is no bone involvement.

The *HyProCure*® extra-osseous talotarsal fixation device is composed entirely of medical grade titanium. Titanium has been found to be the safest material to be implanted into the body. It is non-reactive, lasts a very long time, doesn't set off metal detectors and patients can still have various radiologic studies such as a CT scan or an MRI. The chance of having an allergic reaction to titanium is extremely rare.

There are two main areas to the sinus tarsi. The outer, conically shaped area is the “sinus” portion of the sinus tarsi and the deeper, cylindrically shaped area is the canalis tarsi. The undersurface of the ankle bone and upper surface of the heel bone form the halves of the sinus tarsi. The exact area where stabilization should occur is at the half-way point of this structure or the entrance to the canalis tarsi. This is where the tapered portion of *HyProCure*® maintains the natural opening of the sinus tarsi to allow normal triplane motion to occur.

It should be noted that the sinus tarsi has an oblique orientation. The outer-half is angled more toward the front of the foot and the inner-half is angled toward the back of the foot. The ankle bone (talus) is the most complicated bone of our body and it has more variations than any other bone. Because of the many variables in the anatomy of this area, it is possible that there could be a limitation in the placement of the *HyProCure*® stent within the sinus

Benefit-Risk Analysis of Extra-Osseous Talotarsal Stabilization

tarsi. The canalis tarsi could be extremely narrow, preventing the appropriate placement of the device in this deeper portion. Or there could be angulation irregularity which would lead to the device being placed too deep or too superficial. Remember that surgery is an “art” and is not an exact science like mathematics.

HyProCure® displacement is one of the most common risks as it is not anchored into bone but rather held in place by tissue adherence and the overall bony chamber forming the space. It is possible that the supporting tissues within the sinus tarsi have eroded due to the chronic progression of the disease process. This means there are no tissues within the space to adhere to the device to anchor it. Another possibility is that an important portion of the heel bone has been worn down due to years of the ankle bone grinding on it. In this case, it is possible that the **HyProCure®** device could be placed correctly into the sinus tarsi, but upon weight bearing, the ankle bone would push against the device. If the heel bone has been flattened there would be nothing to support the front side of **HyProCure®**, so it would slip out of place along with the ankle bone. This is a rare but possible scenario.

Generally speaking, it takes about four (4) to six (6) weeks for the soft tissues within the sinus tarsi to adhere to **HyProCure®** locking it within the sinus tarsi. The chance of **HyProCure®** displacement after the four to six week period is less than 1%. Device displacement can range from partial to full. It is quite normal for the device to shift up to a few millimeters from the position it was in intra-operatively. This is due to the fact that **HyProCure®** is inserted while the patient is lying on an operating room table, off their feet (non-weightbearing). When the patient first stands, it is possible for **HyProCure®** to seek its final position, where it naturally needs to be to do what it was designed to do. As long as the desired correction is achieved and the device is in an acceptable position there is no reason for repositioning. As much as a surgeon wants to be as accurate and precise with the device placement as possible, it could be the case that the **HyProCure®** device functions better in another location.

The most common causes of device displacement include being too active too soon, wearing improper or worn out shoes or a traumatic episode such as a severe ankle sprain. The displacement could also occur from an improper decompression of the sinus tarsi, improper device sizing (too small or too large) or incorrect placement.

An important aspect of the procedure is determining the perfect size device for the patient. There are six (6) different sizes of the **HyProCure®** device. One of the limitations of this procedure already mentioned is that it is performed while the patient is off their foot. It simply is not possible to insert the trial sizer into the foot and have the patient stand. Therefore, the surgeon will do their best to select the most appropriate size to achieve the optimum correction. Sometimes, trial sizing will show little to no difference in correction between two sizes. If this should occur the general advice is to go with the smaller size as it is better to have a slight under-correction than over-correction.

Occasionally, patients may experience a clicking sensation in the initial post-procedure time frame. This is not necessarily an indication that something is wrong and it should just be a matter of time for that feeling to resolve on its own. On the other hand, if the clicking persists it could indicate that the device has displaced. A complete displacement of the device will be followed by loss of correction.

Another potential procedure problem is failure to achieve the desired correction. Even if the device is adequately placed there could be unforeseen bony adaptations/variations or severe ligament damage. It is not always possible to predict this scenario prior to surgery. There may also be an inability to place the device in the desired position due to anatomic limitations or restrictions.

There are other risk factors common to all surgical procedures such as delayed incision site healing, suture reaction, nerve entrapment, scar tissue formation and post-procedure infection. Swelling is a normal post-procedure reaction. Depending on the

Benefit-Risk Analysis of Extra-Osseous Talotarsal Stabilization

patient, swelling can range from nearly nonexistent to excessive. It is advised to maintain a low sodium diet and to avoid consumption of excessive liquids. Salt is a magnet for water retention and combined with decreased/minimized walking leads to swelling in the ankle and lower leg. Swelling is only a temporary post-op phenomenon and should resolve over time.

Some degree of pain should be expected since this is a surgical procedure. The amount of pain experienced varies from foot to foot and individual to individual. Everyone has different thresholds for pain. Usually, the pain is simply controlled with anti-inflammatory medication and possibly pain medication. It is very rare for someone to experience severe pain, but again, this is something that cannot be predetermined. Increased swelling usually results in increased pain.

One of the greatest challenges of foot surgery is that the foot is one of the most used parts of your body. It is relatively easy to rest a shoulder, elbow, wrist or hand, but trying to rest your foot is quite difficult. The good news is that if EOTTS was the only procedure performed, you may be allowed to walk on the foot immediately. It is expected there will be a period of abnormal walking. There is a natural guarding mechanism that occurs after surgery that forces one to walk on the outside of the foot. This may be disconcerting. However, once the inflammation within the sinus tarsi subsides, you will be able to walk more normally, on the entire bottom surface of your foot. This sensation of “walking on the outside of the foot” could resolve within a matter of days or it could take several months and even up to a full year. Generally, it is recommended that this procedure is performed one foot at a time for a faster recovery and to lessen potential complications. However, if both feet exhibit the deformity and require stabilization, the first foot will not fully recover until the second foot is also internally stabilized. Think of balancing the tires on one side of your car and not the other.

Once the hindfoot is stabilized there will be many adaptations that may occur. Certain muscles will

not have to work as hard whereas others that have not been “pulling their weight” will have to work a little harder. The same is true of the ligaments and tendons. Not everyone will experience new aches and pains; if these do develop they usually resolve within a short period of time. Occasionally, certain tissues, such as one specific ligament on the front side of the outer ankle bone, may take longer than normal to adapt to the corrected hindfoot alignment. In most cases this will subside on its own by wearing more supportive shoes, taking anti-inflammatory medications, physical therapy, wearing an ankle brace or from a steroid injection(s). Some degree of soreness and pain in this area is a somewhat common side-effect (1 in 10 to 1 in 100 individuals). However, it is uncommon (1 in 100 to 1 in 10 000) for the device to be downsized or permanently removed.

Another important fact is that the *HyProCure*® device is not placed into a joint. Even though *HyProCure*® stabilizes the talotarsal joint complex it is not placed within the joint itself. A joint is formed by the articular or joint surfaces of two or more bones. There is no articular surface within the sinus tarsi and therefore the sinus tarsi is not a joint. However, it is possible that joint fluid will leak out of the large joint behind or in front of the sinus tarsi. This fluid, called synovium could be accumulating within the sinus tarsi. Once an incision is made this fluid can “leak” out of the surgical site until the skin incision has healed. Some individuals have mistaken this fluid leakage as an allergic reaction from the titanium. The chance of synovitis occurring is uncommon (1 in 100 to 1 in 1000 cases). If it does occur this drainage will resolve in a short period of time.

It has been implied that a device in the sinus tarsi could ultimately lead to arthritis within the space or to degenerative bony changes. However, arthritis can only occur within a joint and we have already learned the sinus tarsi is not a joint. It is highly unlikely that a device placed in front of or behind a joint can lead to arthritis. On the other hand, chronic displacement of the ankle bone on the hindfoot bones leads to excessive and abnormal joint motion that will most definitely lead to chronic inflammation of the joint

Benefit-Risk Analysis of Extra-Osseous Talotarsal Stabilization

and eventually arthritis.

It is highly unlikely that anyone would develop increased pain to their knee, hip, or back after this procedure. It could be possible that during the early recovery phase an increased strain could be placed on the rest of the body. This may be due to the altered walking pattern. As soon as walking normalizes, any increased strain to the rest of the body should settle down and resolve.

Finally, it is important to emphasize that nothing works on everyone. There is a reported six percent (6%) permanent removal of *HyProCure*®. This is mainly due to failure of soft tissue adaptation, psychogenic reaction (the device was functioning pain free but the patient was unable to accept the fact that the device was in their body), and post-operative infection (less than 1% chance).

EOTTS, unlike rearfoot reconstructive foot surgery, has never been shown to cause a serious bone or soft tissue infection, has no reported cases of fracture of the ankle or heel bones, has not lead to amputation of the foot or leg, or to any other serious complications.

EOTTS Benefit versus Risk Analysis Summary

Extra-osseous talotarsal stabilization with *HyProCure*® is a minimally invasive, internal, permanent, yet reversible option that has been scientifically shown to realign the hindfoot and at the same time significantly decrease strain to several important structures of the foot and ankle. The positive effects of hindfoot realignment are not limited solely to the foot as there are additional benefits up the musculoskeletal chain. Improved foot function leads to increased walking and a general improvement to overall health and well-being.

Every solution has the potential of creating new problems. This is a surgical procedure and there are potential risks. Overall, these risks are, for the most part, short-term and self-resolving. Should a more serious risk develop, the device can be removed with

very low probability of permanent ill-effects.

The overwhelming majority of both pediatric and adult patients have benefited from the EOTTS with *HyProCure*® treatment option. Adverse events and side effects are generally uncommon; however they do occur. This impact is disproportionate relative to the number of patients receiving a benefit. This is due to the emotional component associated with the risks. The overall life-changing benefits of EOTTS with *HyProCure*® far outweigh the potential risks.

EOTTS – No Guarantees

My foot surgeon has examined my foot/feet clinically and radiographically and determined I have flexible displacement of the ankle bone (talus) on the heel bone (calcaneus). I understand that this is an internal deformity and I believe it is best corrected internally. External measures such as pads, shoes, arch supports, stretching/strengthening and/or braces have either failed to correct or will not provide the correction needed for my deformity. Therefore, I have chosen to undergo an Extra-Osseous TaloTarsal Stabilization (EOTTS) procedure. This EOTTS surgical procedure involves the cutting of soft tissues to allow for the insertion of a titanium medical device into the naturally occurring space in-between the ankle and heel bones.

I understand there is no such thing as a complication-free surgical procedure. Any surgical procedure has potential risks. I have reviewed the “Risk-Benefit Analysis of EOTTS with *HyProCure*®” and understand it fully. I have had an opportunity to ask any questions of my surgeon and those question(s) have been answered to my satisfaction. I feel that I will benefit from this procedure and it makes sense to me.

I understand there is no guarantee that this procedure will work and while the vast majority of patients who have undergone this procedure have benefited from it, there are a small minority of patients who have not benefitted and ultimately had to have the device removed through no fault of the device or their surgeon.

Patient Name: _____ Date: _____

Patient/Guardian's Signature: _____

Witness Signature: _____

Relationship To Patient/Title: _____ Date: _____

Date of Procedure(s): _____

This page intentionally left blank.

Extra-Osseous TaloTarsal Stabilization with Internal Fixation Surgical Consent Addendum

It is important that you read this information completely and carefully. Please initial each section, indicating that you have read the section and understand its meaning.

Dr. _____ has explained to me that I have an abnormal alignment between my ankle bone (talus) and the other bones of my rear-foot (tarsal bones) that requires internal stabilization.

(Initial here) _____

I am aware that there are non-surgical forms of treatment, including: no treatment, splints, padding, arch supports/orthotics, medications and special shoes. I am aware there are risks and other potential complications that can be associated with these forms of treatment including progression of the deformity and under-treatment of the condition.

(Initial here) _____

I have chosen, after much thought and consideration, including a thorough discussion with my physician, review of various forms of information including websites and brochures, to treat my condition by undergoing a surgical procedure to insert the internal bone stabilization device into my

Right / Left hindfoot.

(PLEASE CIRCLE)

(Initial here) _____

I understand that there are potential risks and complications of the insertion of this device into my foot that include, but are not limited to: migration or displacement of the device, synovitis (inflammatory reaction with drainage), prolonged soreness from the soft tissues adjusting to the stabilized correction, possibility of not tolerating the correction achieved by the procedure, prolonged period of "adjustment" associated with a period of pain and abnormal walking due to the new foot position, unsatisfactory results, possibility of under- or overcorrection, possibility of improper positioning of the device, healing issues, scarring, need for further surgery (the need to remove the device and/or additional surgical procedures), as well as other risks associated with any surgical procedure, such as infection, blood clots, loss of limb or life, allergies and anesthetic risks.

(Initial here) _____

The post-procedure course has been explained to me and I will follow these instructions to the best of my abilities.

(Initial here) _____

This page intentionally left blank.

PRE-EOTTS Surgical Instructions

To minimize the risks of your operative procedure, please follow these instructions:

1. Your talotarsal stabilization procedure has been scheduled for:

Day: _____ Date: _____

Time: _____ AM / PM *(Please Circle)*

2. Facility Name & Location: _____

3. **DO NOT** eat or drink after midnight before your surgery, unless instructed otherwise.

4. You should have your prescriptions filled and obtain your crutches or walker before surgery (if prescribed by your doctor).

5. Talk to your doctor about any medications you currently take and whether you should temporarily stop or reduce these medications. This includes both OTC (over the counter) and prescription medicines.

6. If you smoke, it is advisable for you to stop smoking prior to any surgical procedure and while you are recovering from surgery.

7. Arrange to have someone drive you home following surgery.

8. If you are under 18, a legal guardian or parent must sign an authorization for surgery.

9. Other: _____

I hereby certify by my signature that the above instructions were fully explained to me, that to the best of my ability I will endeavor to follow such instructions, and should any problems arise, I will contact the office immediately.

Signature: _____ Date: _____

Printed Name: _____

This page intentionally left blank.

POST-EOTTS Instructions

The amount of discomfort and swelling will vary from patient to patient, therefore, please follow these instructions:

1. While returning home from surgery, sit sideways in the back seat of the car with the surgical foot elevated.
2. Remain quiet and off your feet as much as possible for the first 3-5 days. Place a pillow under the calf of your leg so the surgical foot is elevated. It is important to walk as little as possible during this time.
3. Place an ice bag (frozen peas work the best) wrapped in a moist towel over the surgical area 15 minutes out of every hour. This should be continued, as needed, for several weeks following surgery. Ice will significantly decrease inflammation and post-op pain.
4. Remove the dressings after 3 days and apply a regular, self-adhesive bandage; change twice daily.
5. Wear a new, supportive shoe. A “worn out” shoe will prolong your recovery.
6. Make sure the shoe you are wearing does not rub against the incision area.
7. **DO NOT** apply any ointments/gels/creams to the incision area. **DO NOT** apply hot water bags or electric heating pads to your foot; this will increase your pain.
8. Keep the operative area completely dry. If the bandage accidentally gets wet, dry immediately with an absorbent towel and call this office.
9. Your bandages may become somewhat bloody. Should this occur, do not become alarmed. However, if there is active and persistent bleeding, call this office.
10. If it seems your anti-inflammatory medication is not decreasing your pain, call this office.
11. Nausea and light-headedness sometimes occur due to medication(s). If this happens, stop taking the pain pills and give the office a call. Make sure to eat prior to taking pain medication.
12. Follow a light diet and abstain from the use of alcoholic beverages while taking medications. Do not eat salty foods or drink lots of fluid as this will increase your swelling.
13. If your temperature goes over 101° F, call the office.
14. Your next appointment is: _____
15. Should you incur any other problems not discussed in these instructions, please telephone immediately until you reach the Doctor or a member of his office staff.

I hereby certify by my signature that the above instructions were fully explained to me, that to the best of my ability I will endeavor to follow such instructions, and should any problems arise, I will contact the office immediately.

Signature: _____ Date: _____

Printed Name: _____

This page intentionally left blank.

Post-EOTTS Hints

1. Stay off your foot as much as possible.

Every step you take leads to increased trauma to the surgical site. The highest level of post-procedure inflammation is in the first three (3) to five (5) days. Rest and elevate your foot/feet as much as possible during this time.

2. Take an oral anti-inflammatory (if prescribed).

The primary reason for post-procedure pain is inflammation. A pain pill masks the pain, but does not treat the underlying reason the pain is still present – inflammation. Make sure the oral anti-inflammatory is working. There are many different brands; one could be effective for one person while not having any effect for someone else. You should feel at least some relief within a half-hour after taking the anti-inflammatory medication.

3. Take at least one pain pill prior to the local anesthetic wearing off after the procedure.

This helps to make a smooth transition from “numb” to “not-numb.”

4. Pain pill use should be reserved for extreme pain.

You should take one pain pill prior to your anesthetic wearing off the day of surgery, possibly one prior to going to bed that evening and one the next morning. After that, pain-pill use should be a last resort if the anti-inflammatory medication is not working. Just like the anti-inflammatory medication, make sure the pain medication is working. If you don't feel any improvement in the pain within a half-hour, it may not be effective for you.

5. Ice is your best friend. Ice helps to decrease inflammation and swelling.

Also ensure that you elevate your foot at least 10 to 15 minutes an hour. Ice should be used hourly the first 3 to 5 days, and then slowly decreased. However, ice should be used at least once or twice in the evening for several weeks following surgery. A simple concept is using a moist dish towel and a bag of frozen peas. Application for approximately 15 minutes is usually sufficient.

6. Bandages must be applied to keep the site of incision clean and dry.

However, make sure your bandages are not contributing to post-procedure pain. Your foot may develop some swelling and the bandage can act as a tourniquet. If your bandage feels too tight and your toes are swelling, have the bandage replaced.

7. New shoes will aid in a quicker recovery.

After your procedure, it is extremely important not to wear your old shoes. Throw out worn out shoes, as they will lead to increased strain on your tissues. The wear pattern on these shoes will counter-act the correction.

8. “Use it or lose it” does apply.

As instructed above, you want to stay off your foot as much as possible, especially in the first few days post-procedure. However, you do need to use your foot. If you “baby” your foot too much it will take longer for the soft tissues to adapt to their new functions.

9. “No Pain, No Gain” also applies.

You do need to use your foot, but “listen” to your foot; it will let you know when you are doing too much. When your foot really gets sore, take a break and let it rest. After a few moments you should be able to do more. Be sensible.

10. Be patient, remember that you have been standing, walking and running on misaligned feet for years.

While this procedure takes a relative short time perform, it may take up to a year for the tissues within your foot and ankle to adjust.



Graham International Implant Institute

16137 Leone Drive, Macomb, MI 48042 | 1-888-566-6459 | <http://www.grahamiii.com>